

# Trucs et astuces dans la prise en charge des patients complexes: CTO

Dr Nicolas Boudou  
CHU Rangueil  
Toulouse

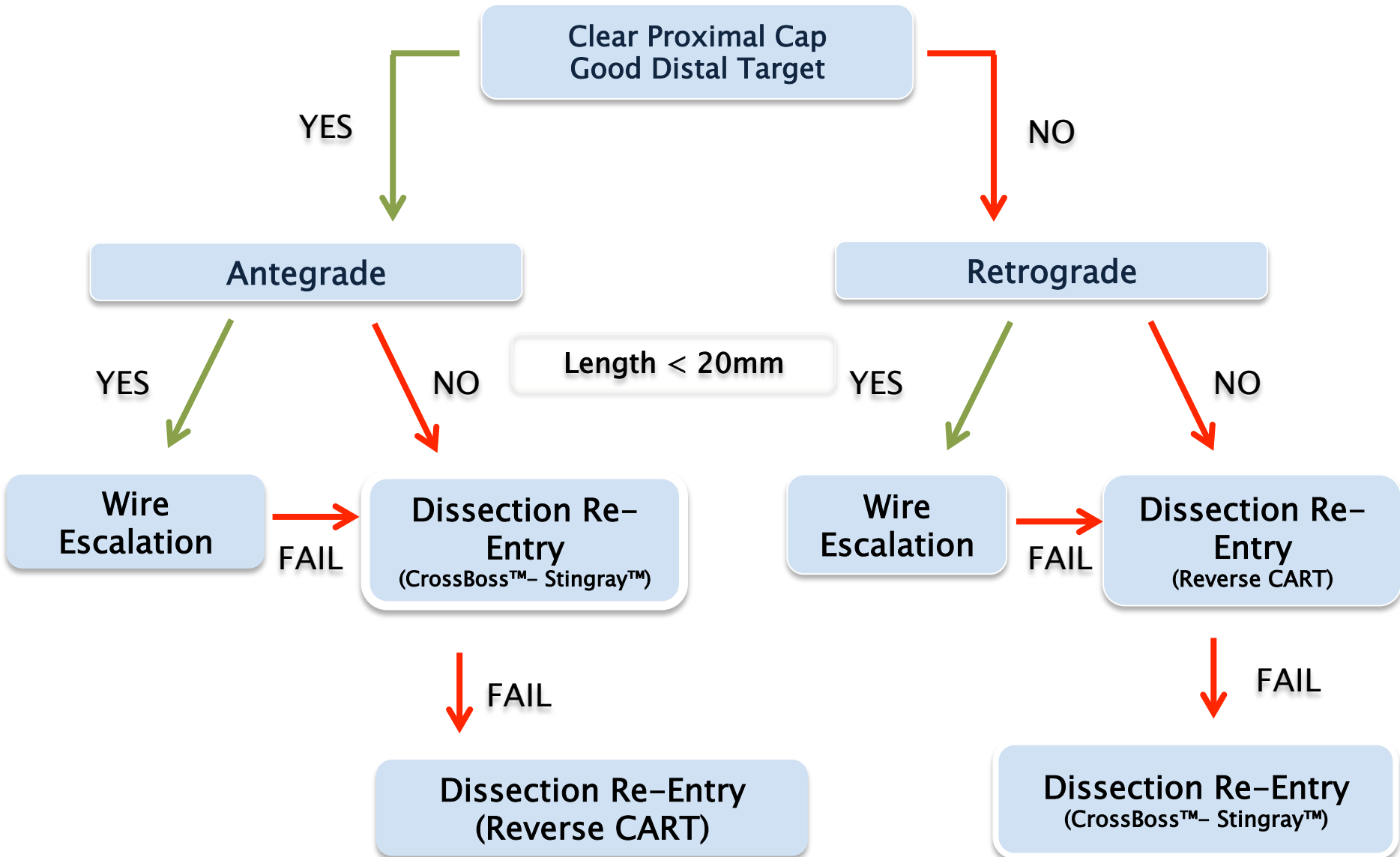


# Déclaration de conflits d'intérêt

**Orateur:** Dr Nicolas Boudou

Consultant: Boston Sc, Terumo

# The Hybrid Algorithm




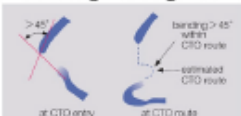




# Predicting Successful Guidewire Crossing Through Chronic Total Occlusion of Native Coronary Lesions Within 30 Minutes

The J-CTO (Multicenter CTO Registry in Japan) Score as a Difficulty Grading and Time Assessment Tool

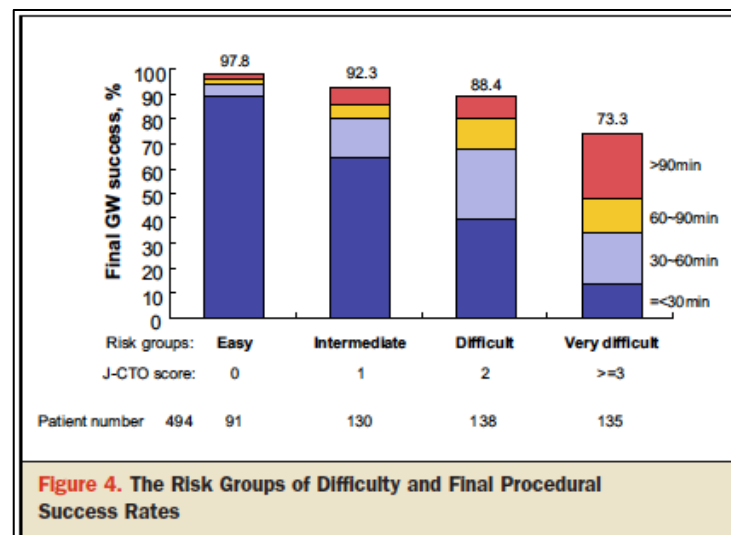
## J-CTO SCORE SHEET

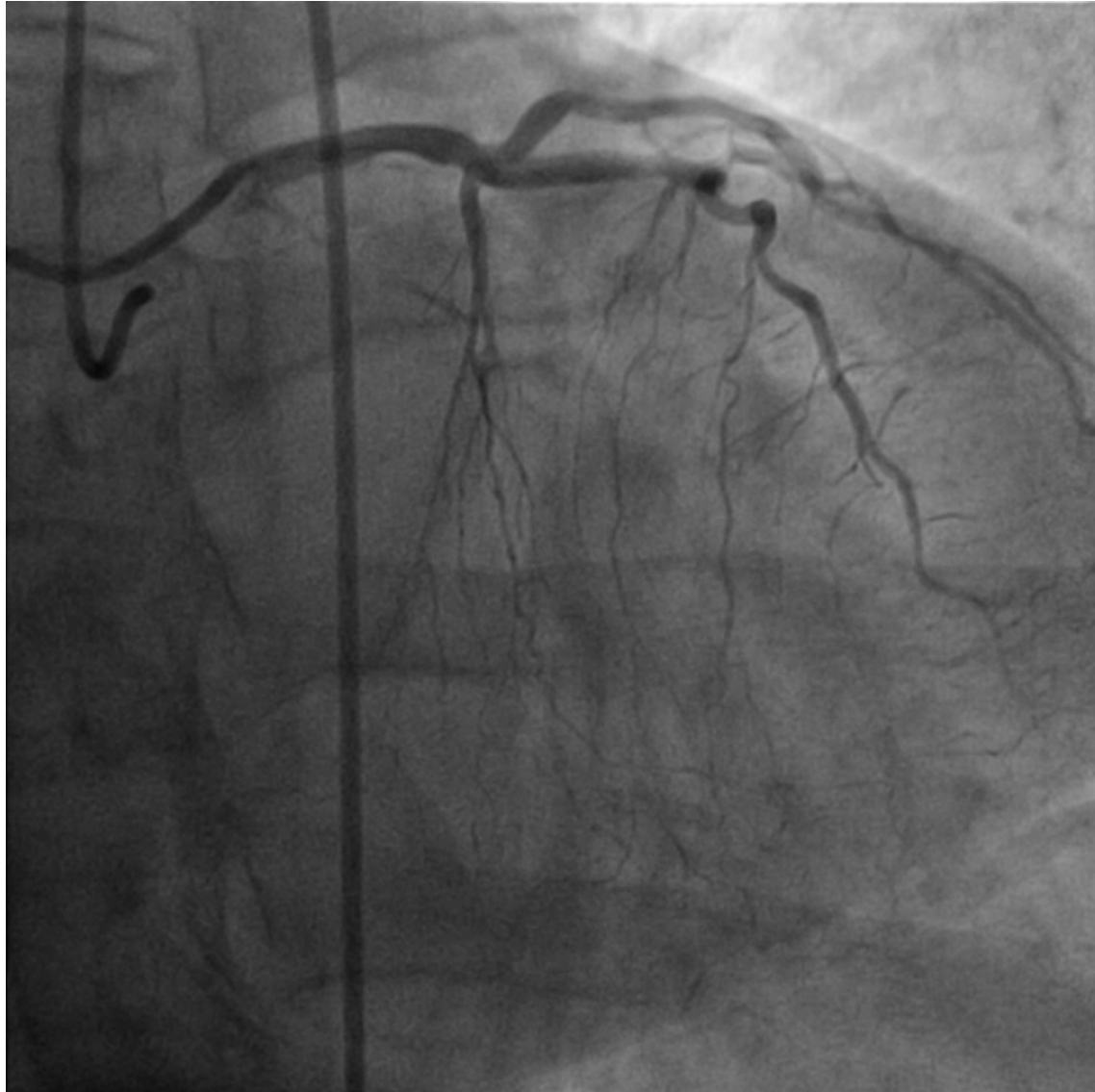
Version 1.0

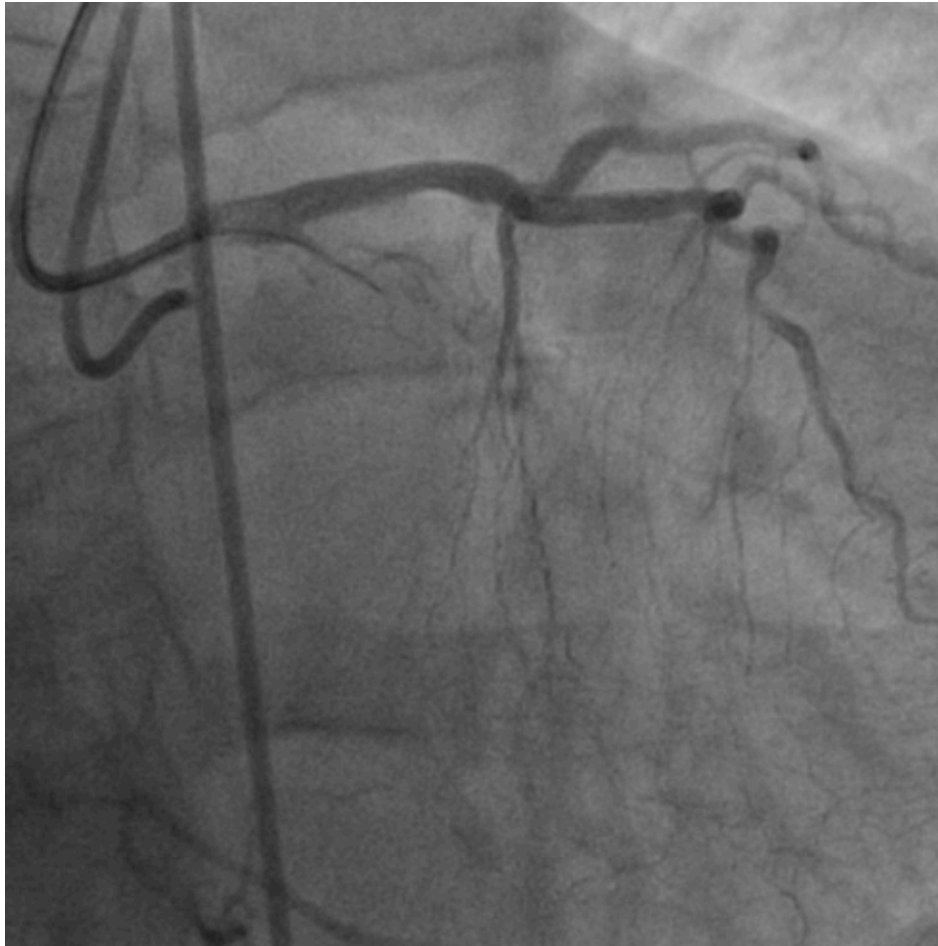
Variables and definitions		
<p><b>Tapered</b></p> 	<p><b>Blunt</b></p> 	<p><b>Entry shape</b></p> <input type="checkbox"/> Tapered (0) <input type="checkbox"/> Blunt (1) point
<p><b>Calcification</b></p> 		<p>Regardless of severity, 1 point is assigned if any evident calcification is detected within the CTO segment.</p> <p><b>Calcification</b></p> <input type="checkbox"/> Absence (0) <input type="checkbox"/> Presence (1) point
<p><b>Bending &gt;45degrees</b></p> 		<p>One point is assigned if bending &gt; 45 degrees is detected within the CTO segment. Any tortuosity separated from the CTO segment is excluded from this assessment.</p> <p><b>Bending &gt;45°</b></p> <input type="checkbox"/> Absence (0) <input type="checkbox"/> Presence (1) point
<p><b>Occlusion length</b></p> 		<p>Using good collateral images, try to measure "true" distance of occlusion, which tends to be shorter than the first impression.</p> <p><b>Occl.Length</b></p> <input type="checkbox"/> <20mm (0) <input type="checkbox"/> ≥20mm (1) point
<p><b>Re-try lesion</b></p> <p>Is this Re-try (2<sup>nd</sup> attempt) lesion? (previously attempted but failed)</p>		<p><b>Re-try lesion</b></p> <input type="checkbox"/> No (0) <input type="checkbox"/> Yes (1) point
<p>Category of difficulty (total point)</p> <input type="checkbox"/> easy (0) <input type="checkbox"/> Intermediate (1) <input type="checkbox"/> difficult (2) <input type="checkbox"/> very difficult (≥3)		<p><b>Total</b></p>  points

Morino et al.

## Development and Validation of the J-CTO Score







## CTO

- moignon effilé
- Courte
- Rectiligne

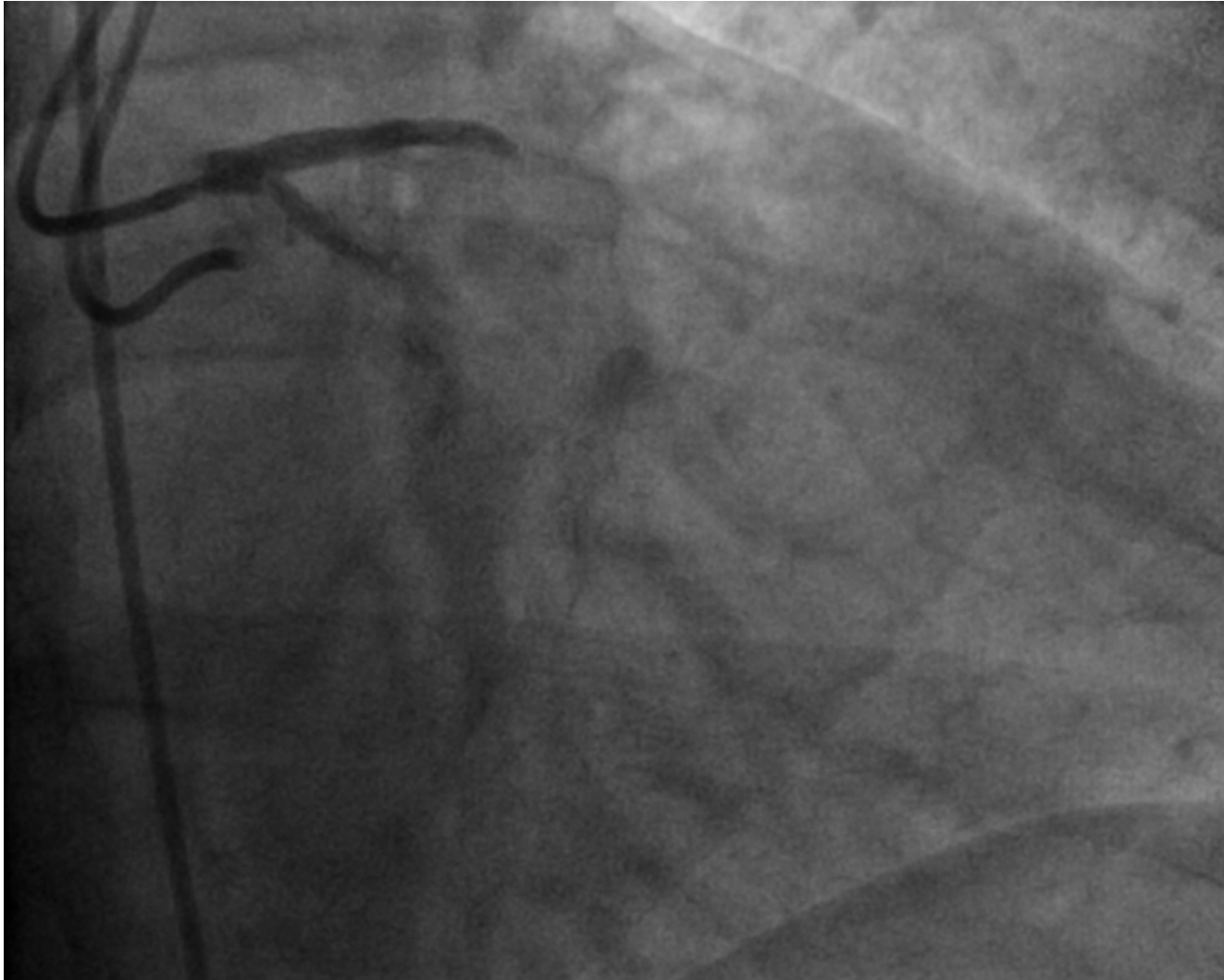
Microcathéter

Guide soft Fielder XT

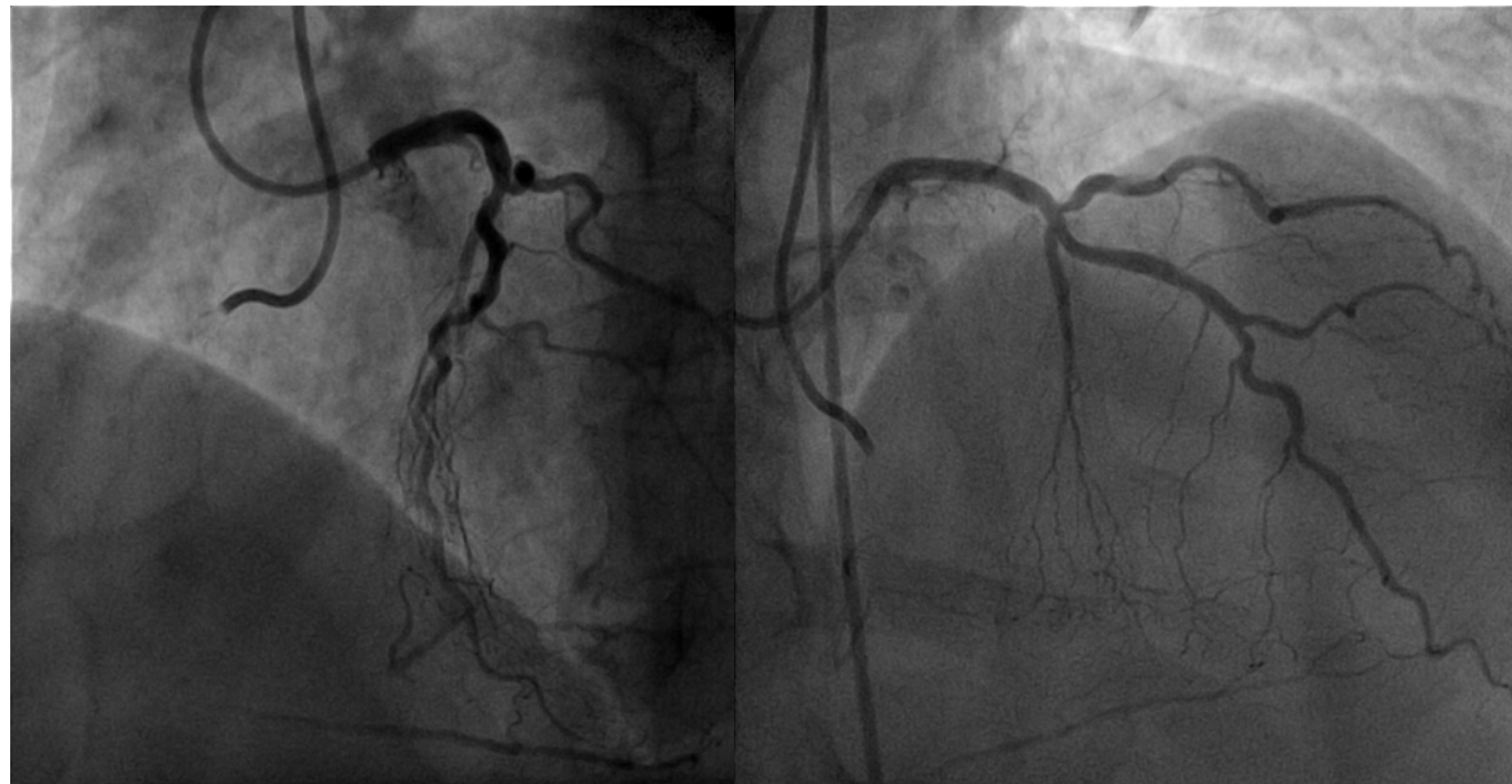
Puis

Guide Rigide (Progress  
140T)



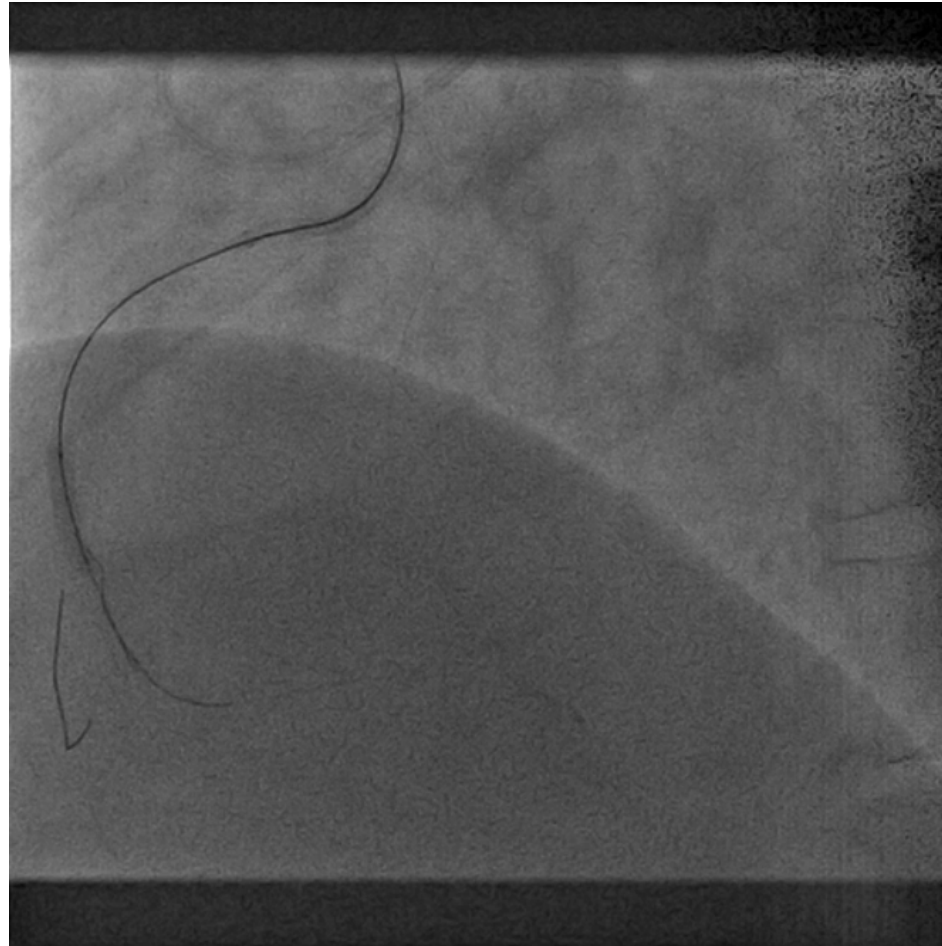


**Final post implantation d'un stent actif Synergy (2.75x24mm)**



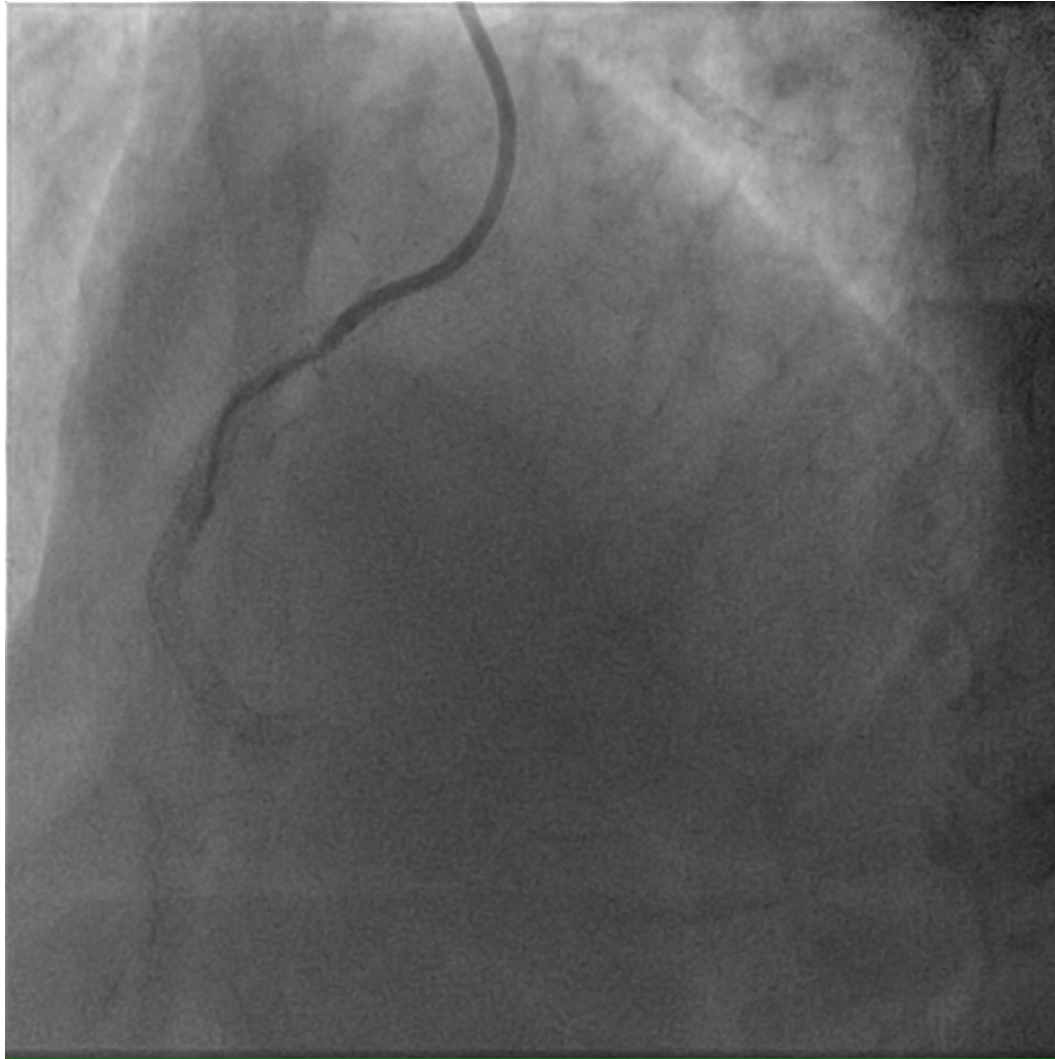

# Dissection réentrée rétrograde: Reverse CART



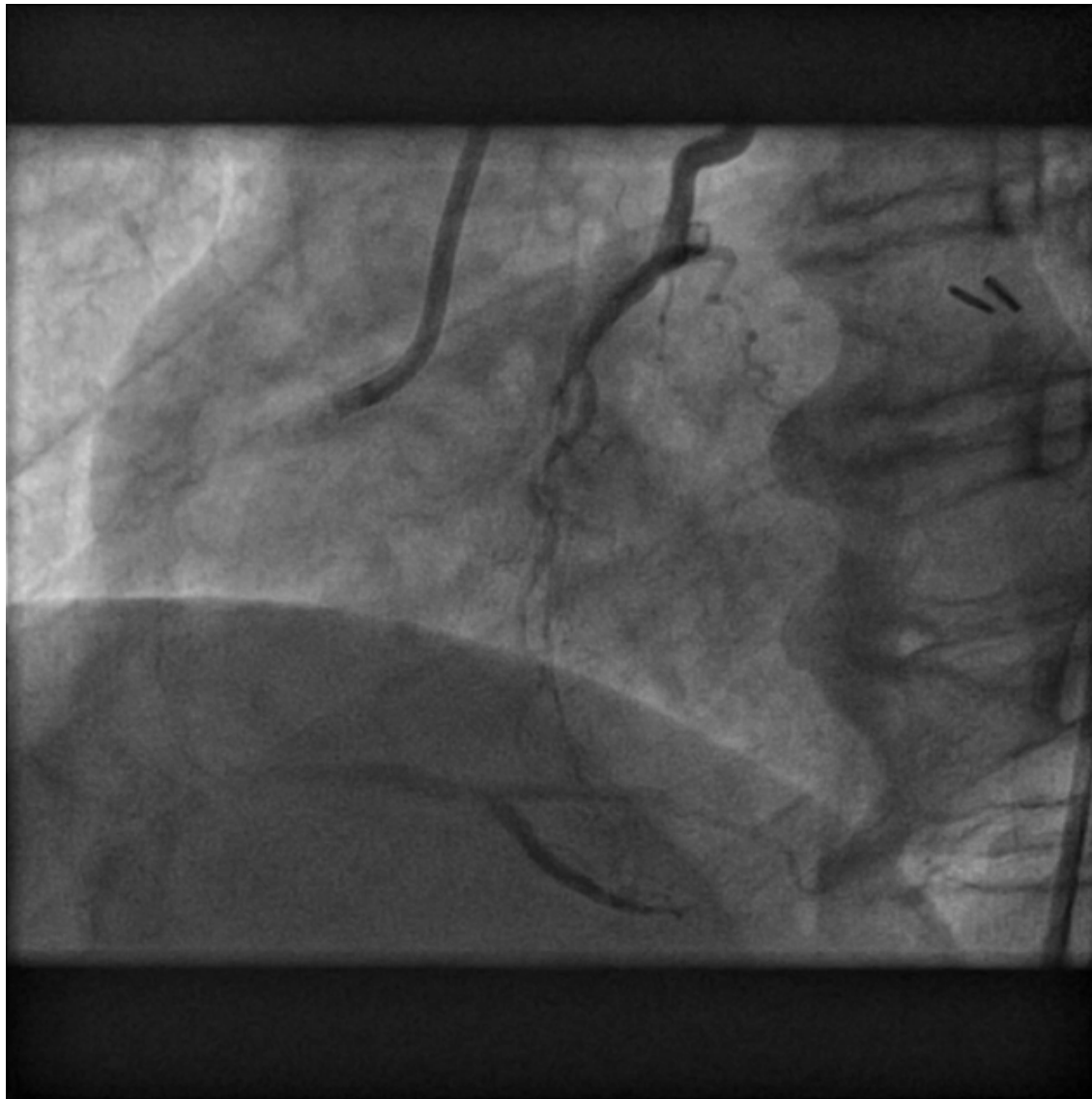- Abord rétrograde via une septale rectiligne
- Echec de franchissement par un guide
- Dissection réentrée rétrograde: REVERSE CART

# Dissection réentrée rétrograde: Reverse CART

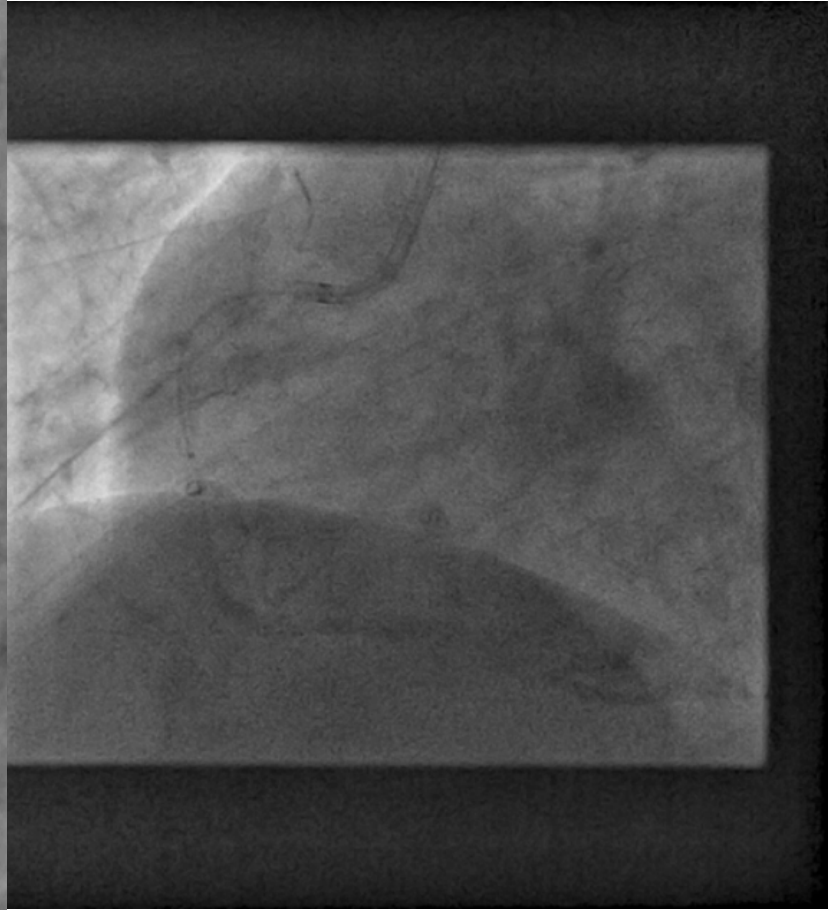
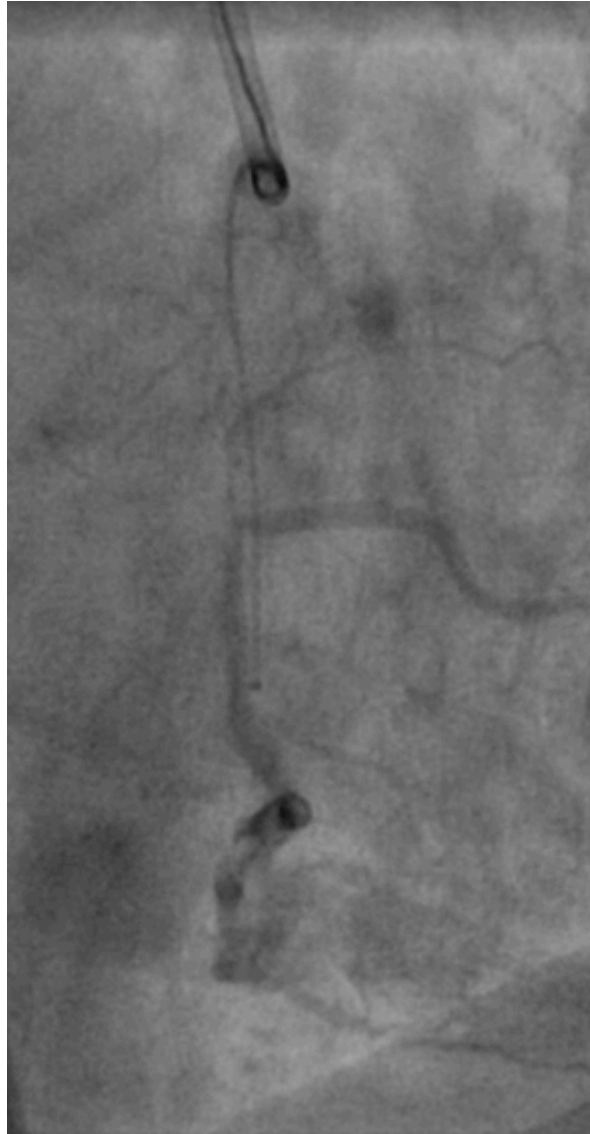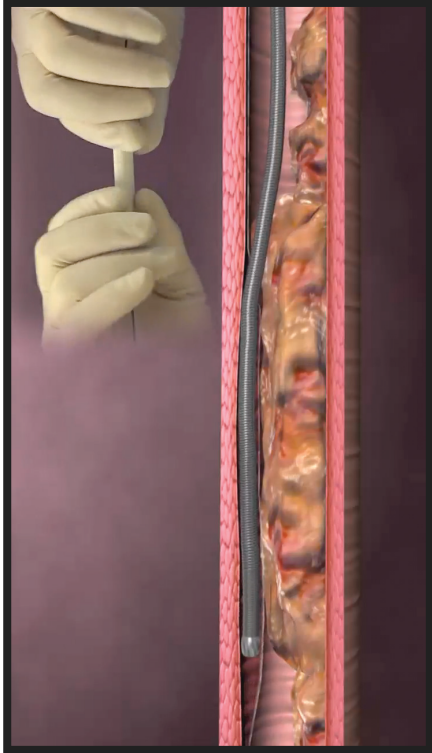


**Résultat final. Implantation de trois stents actifs Synergy**

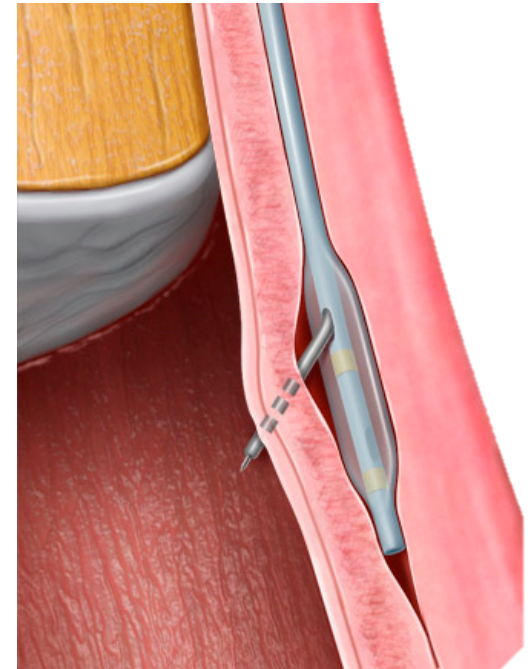
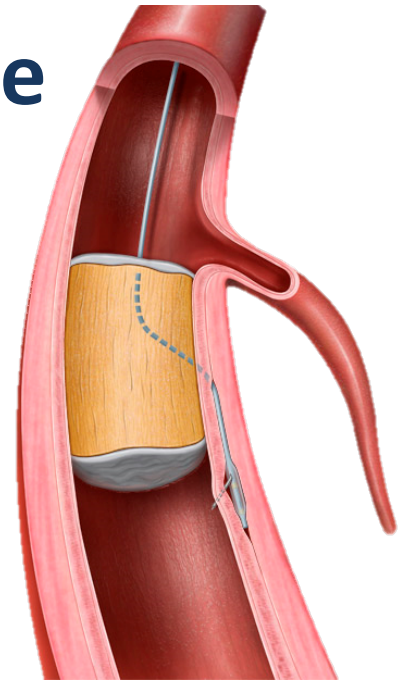
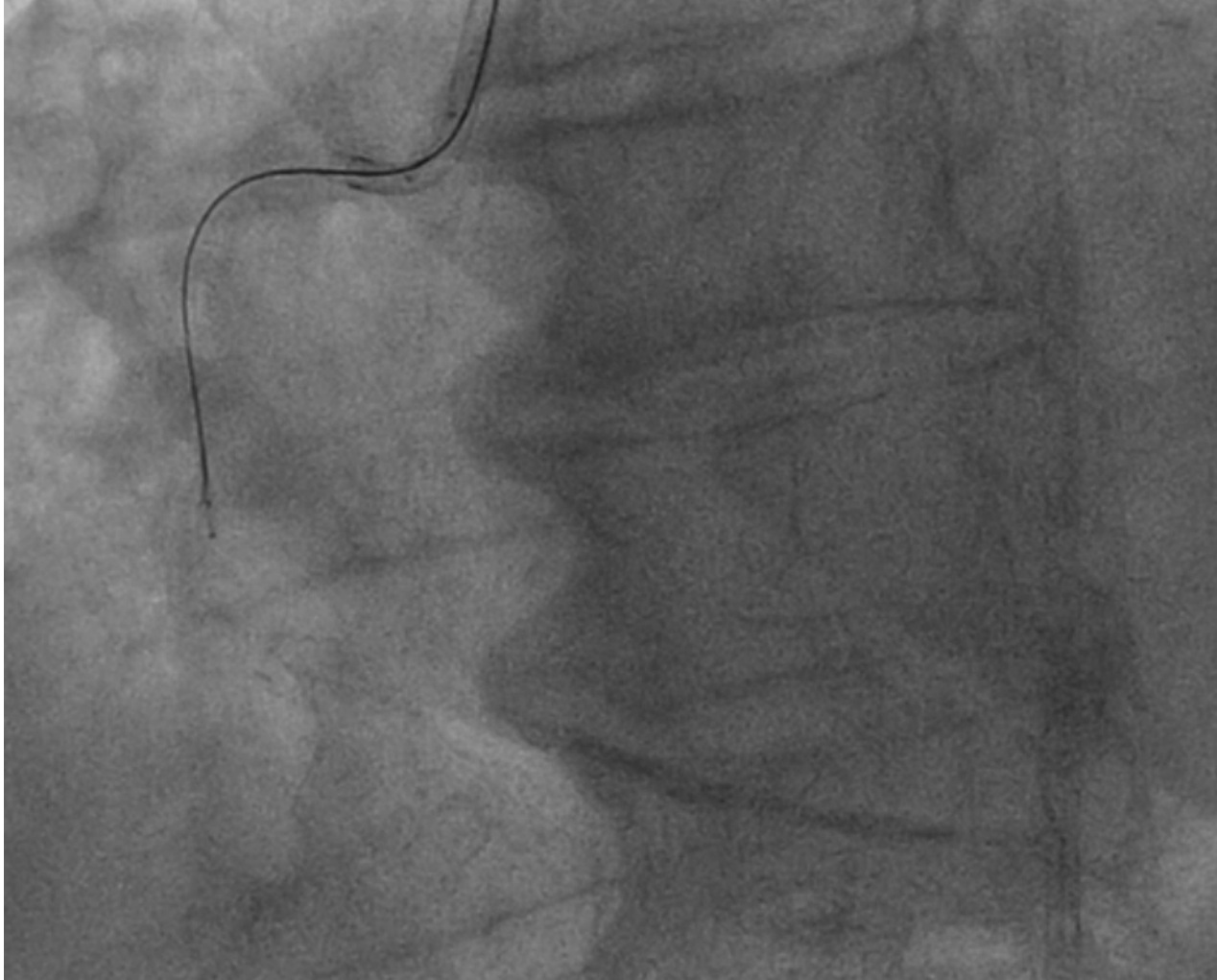
# Dissection réentrée antérograde



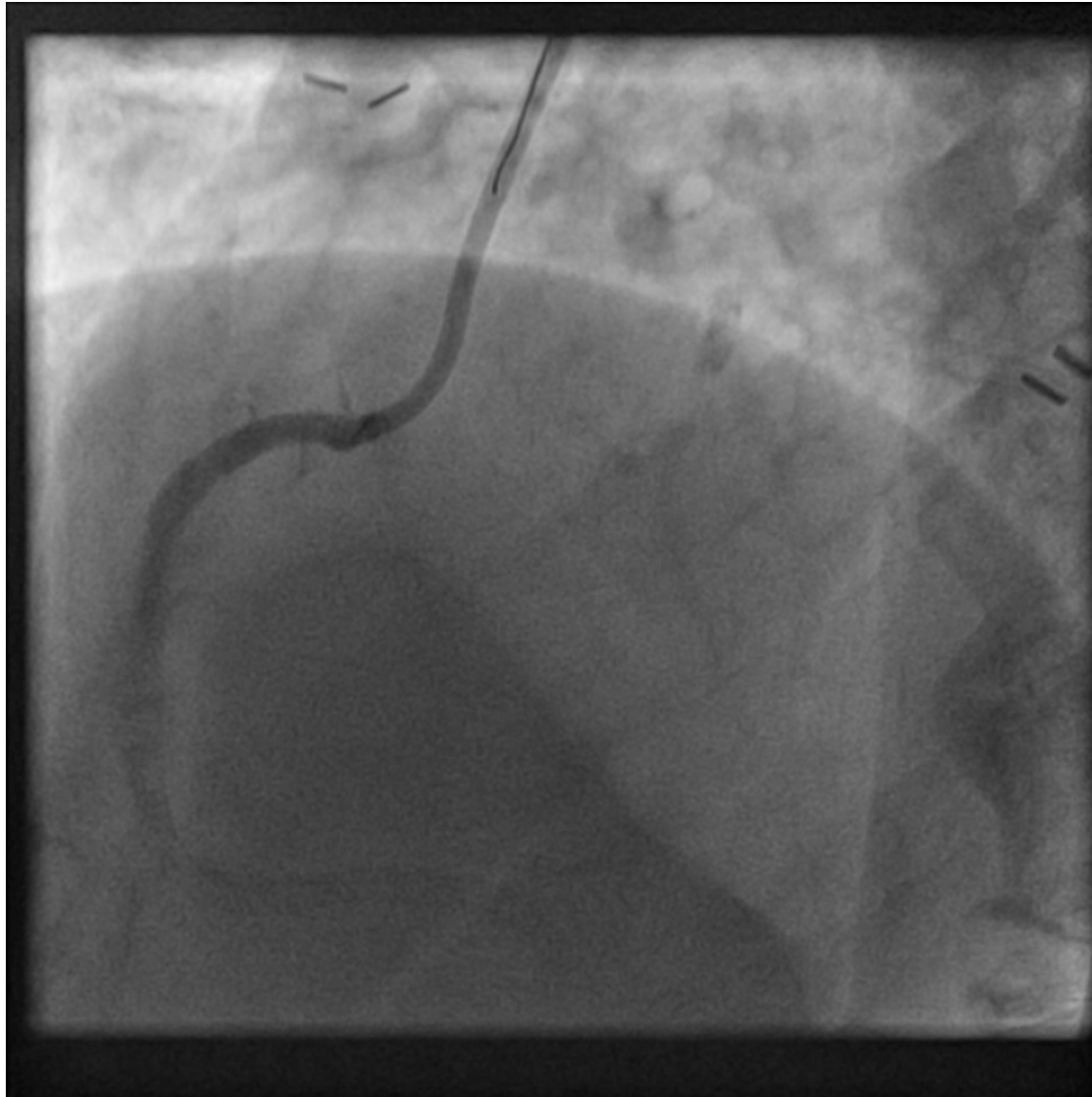
# Dissection réentrée antérograde



# Dissection réentrée antérograde



# Dissection réentrée antérograde



# Conclusion

- Matériel à connaître:
  - guides, microcathéter,...
- Techniques à connaître:
  - Franchissement au guide
  - Franchissement par dissection réentrée
- Trucs et astuces multiples