

# CasEus Belli

Dr P. Leddet, Dr P. Couppié, Dr F. De Poli, Dr S. Uhry, Dr M. Hanssen  
CH Haguenau

# Conflits d'intérêt

- Aucun

# Mme Angélique S.

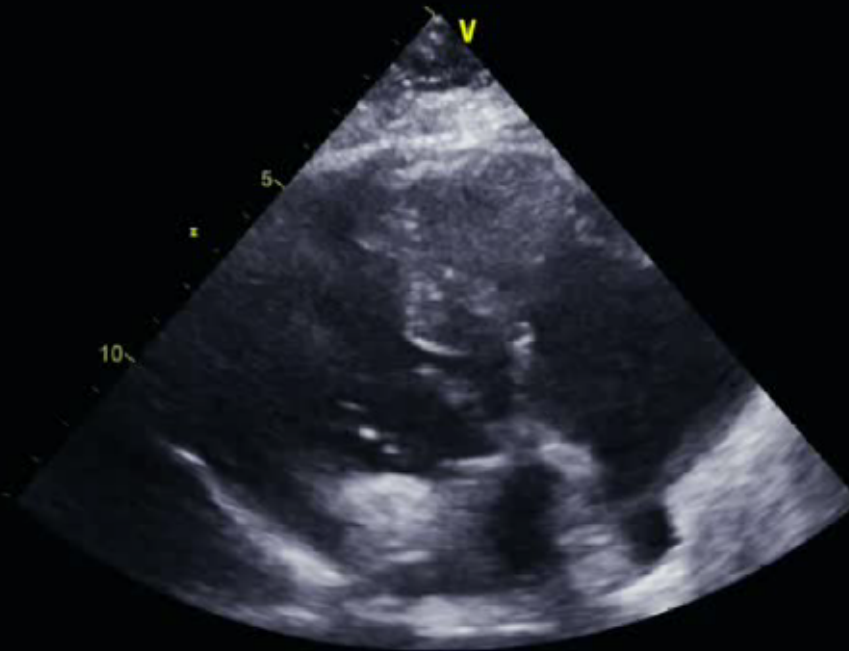
- Patiente de 70 ans,
- Bilan pré-opératoire d'un cancer du sein,
- Asymptomatique sur le plan cardio-vasculaire,
- Pas d'antécédent notable.

CH HAGUENAU  
20/10/14 9:09:10

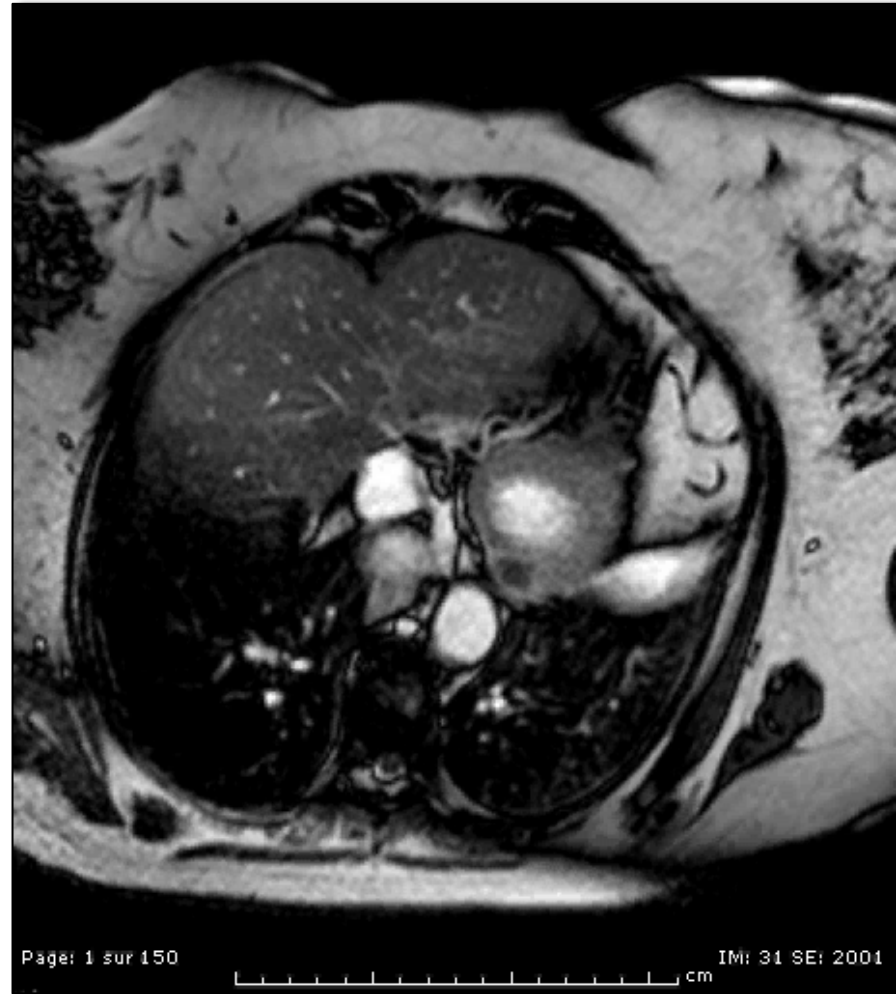
M5S  
CAR GE

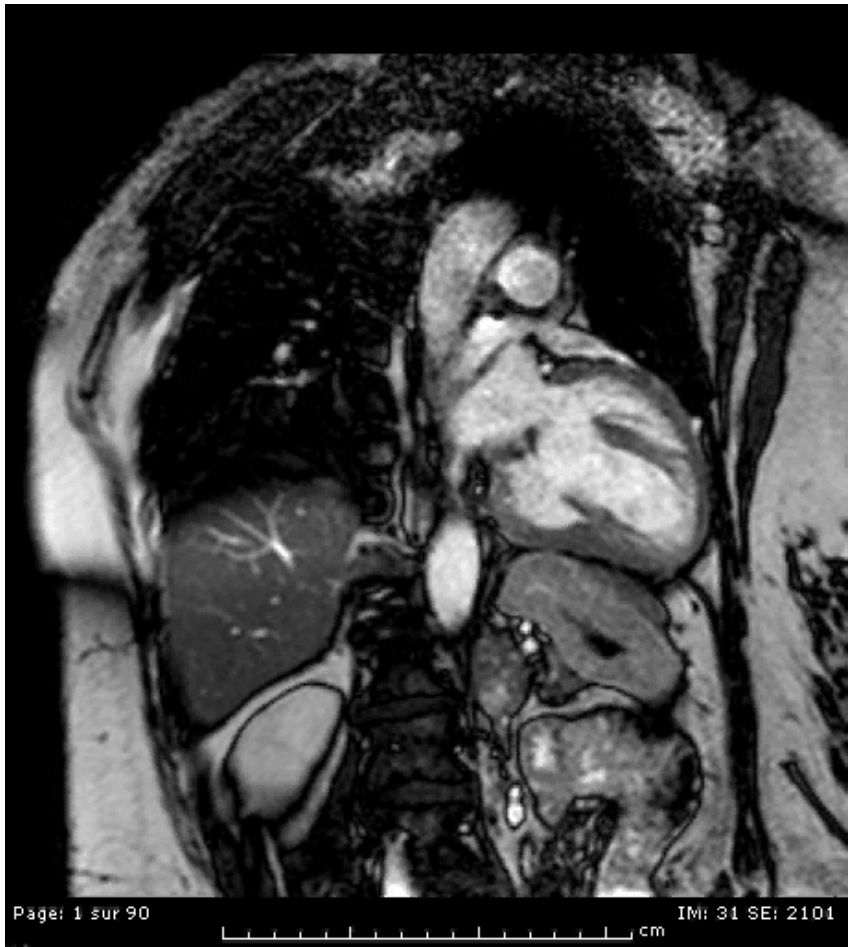MI 1.4  
TIs 0.5

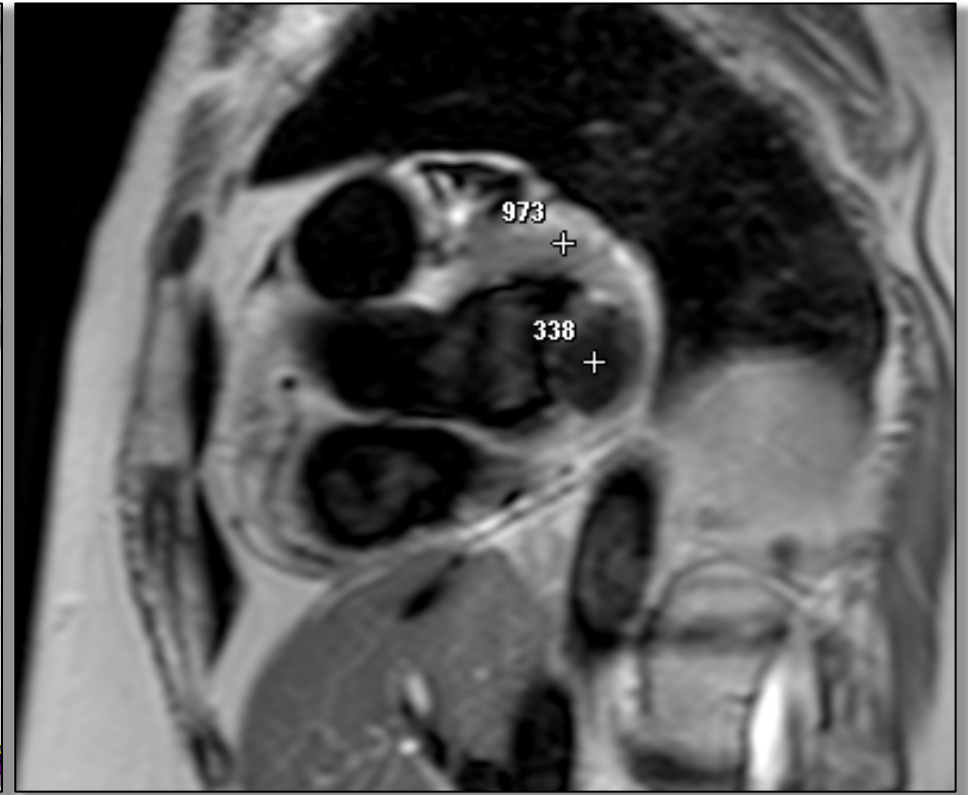
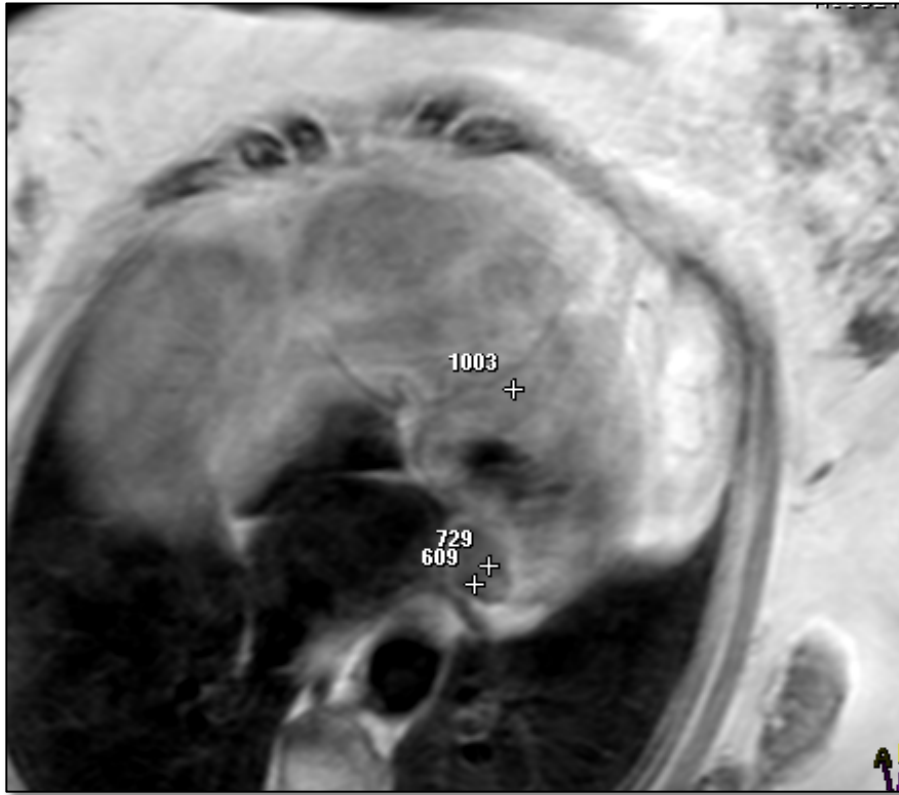
CTO

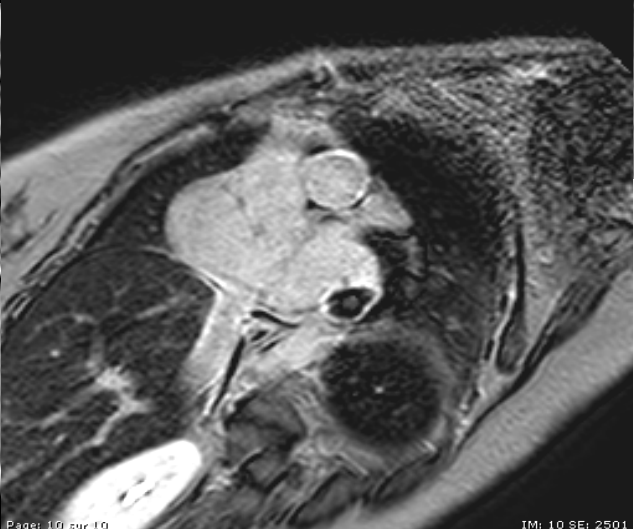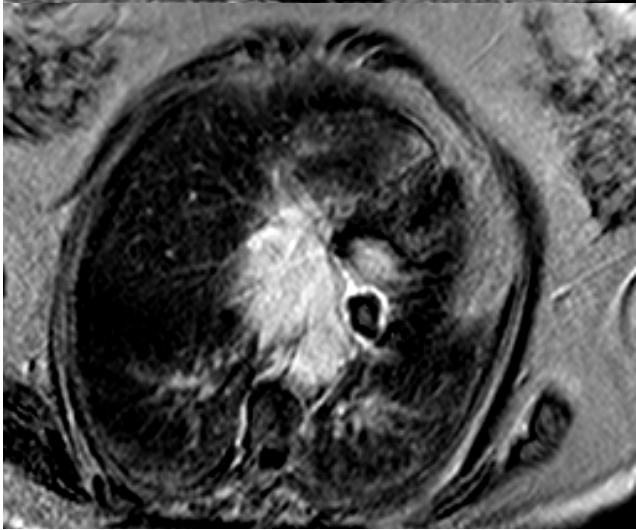
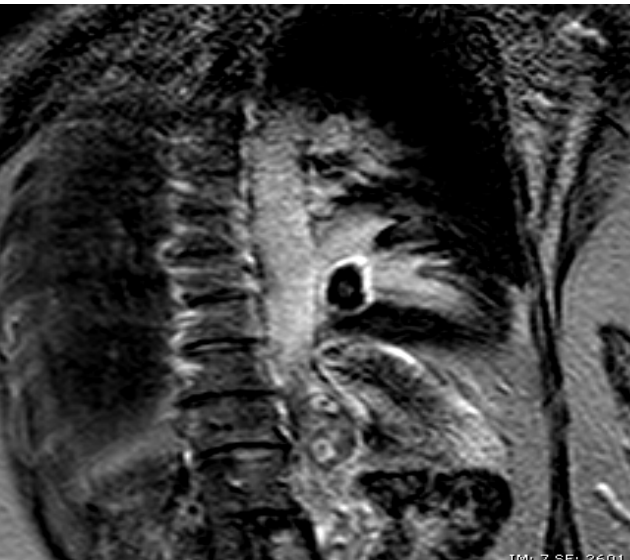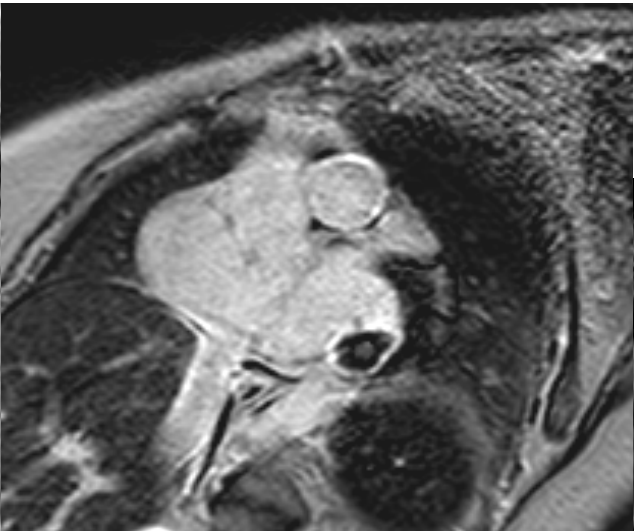
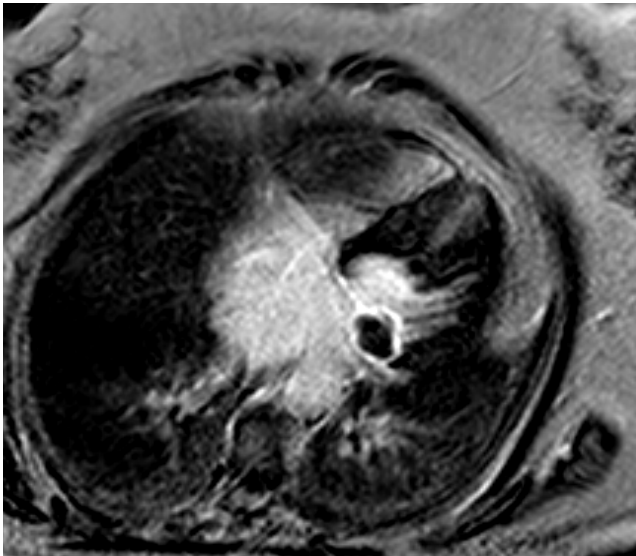


75  
HR







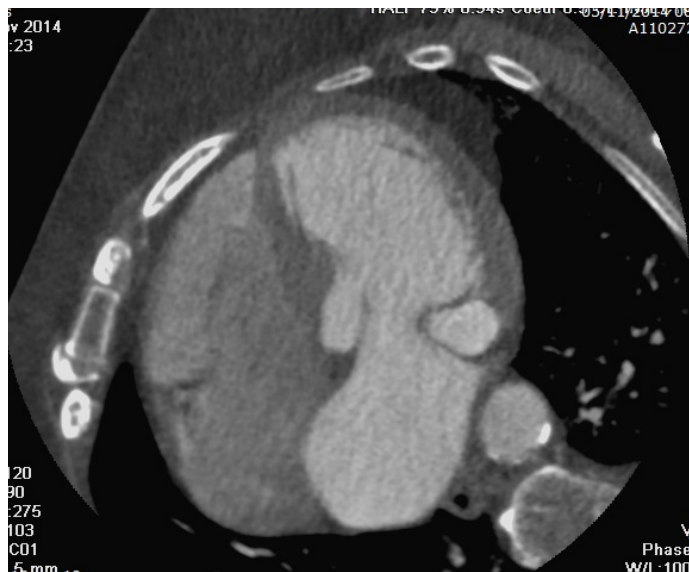

Page: 10 of 10

TM: 10 SE: 2501

TM: 7 SE: 2601

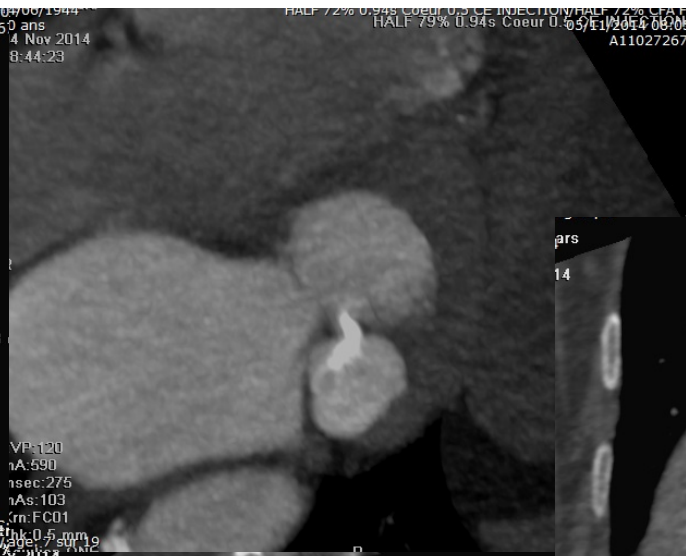



Nov 2014  
08:23

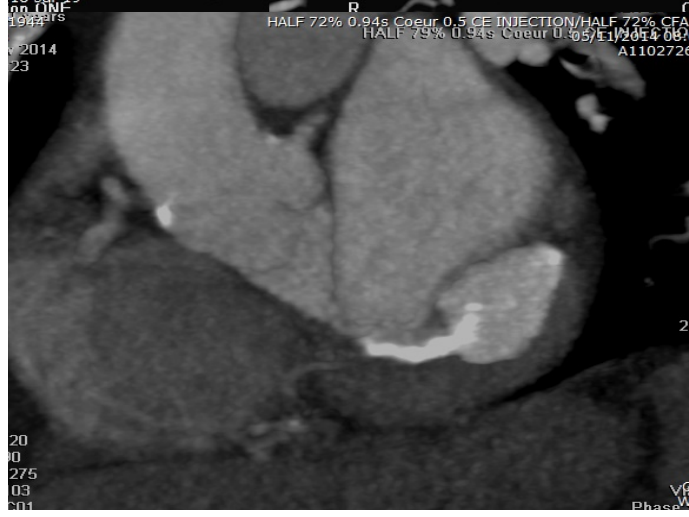HALF 75% 0.94s Coeur 0.5 CE INJECTION / HALF 72% CFA FC  
A11027267  
4 Nov 2014  
08:44:23

VP:120  
mA:590  
ms:275  
kV:103  
mAs:FC01  
Vr:0.5  
W/L:1000/200  
Phase %87.5  
W/L:1000/200  
OR:18



HALF 72% 0.94s Coeur 0.5 CE INJECTION / HALF 72% CFA FC  
HALF 79% 0.94s Coeur 0.5 CE INJECTION / HALF 72% CFA FC  
A11027267  
4 Nov 2014  
08:44:23

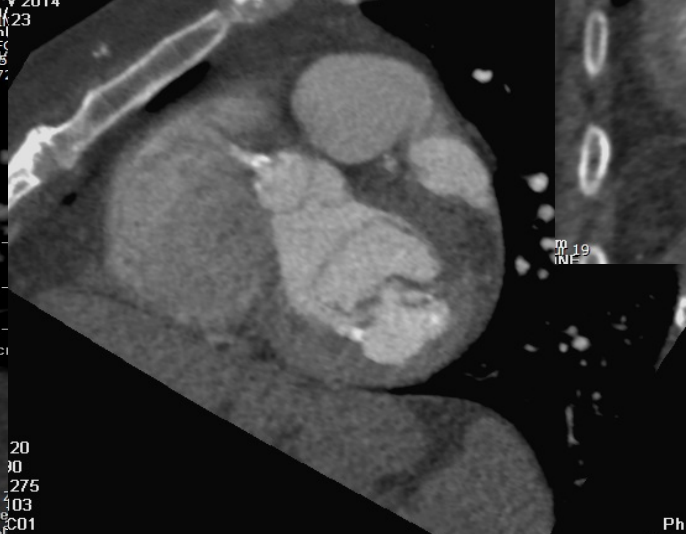
VP:120  
mA:590  
ms:275  
kV:103  
mAs:FC01  
Vr:0.5  
W/L:1000/200  
Phase %87.5  
W/L:1000/200  
OR:18



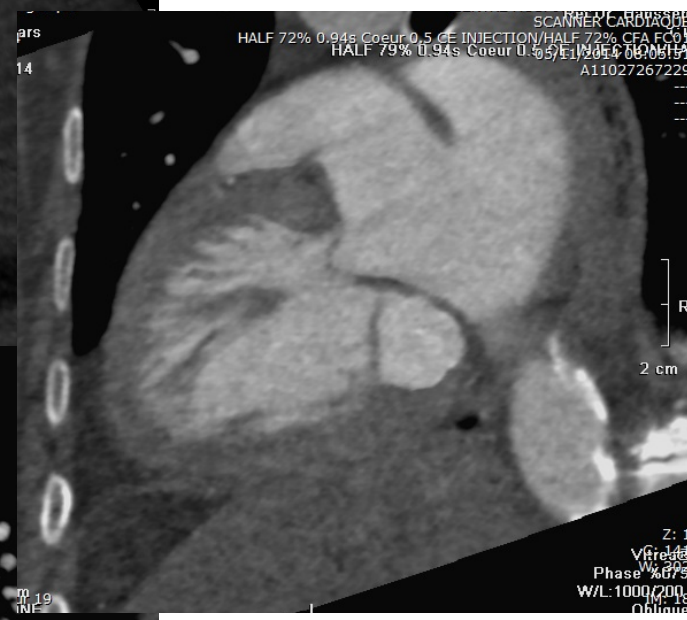Nov 2014  
08:23

HALF 72% 0.94s Coeur 0.5 CE INJECTION / HALF 72% CFA FC  
HALF 79% 0.94s Coeur 0.5 CE INJECTION / HALF 72% CFA FC  
A11027267

VP:120  
mA:590  
ms:275  
kV:103  
mAs:FC01  
Vr:0.5  
W/L:1000/200  
Phase %87.5  
W/L:1000/200  
OR:18



VP:120  
mA:590  
ms:275  
kV:103  
mAs:FC01  
Vr:0.5  
W/L:1000/200  
Phase %87.5  
W/L:1000/200  
OR:18

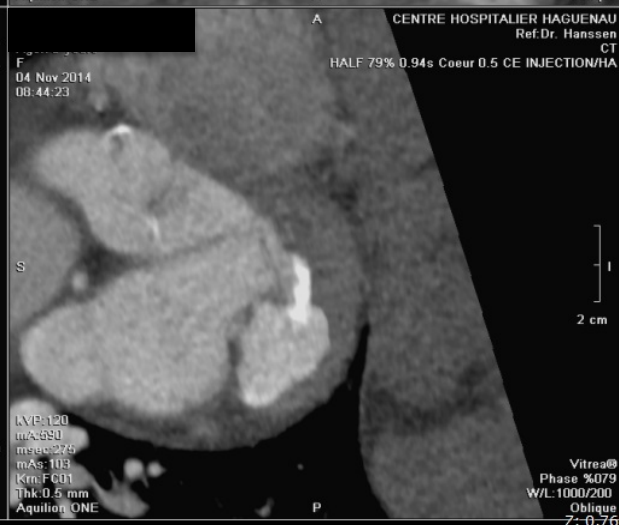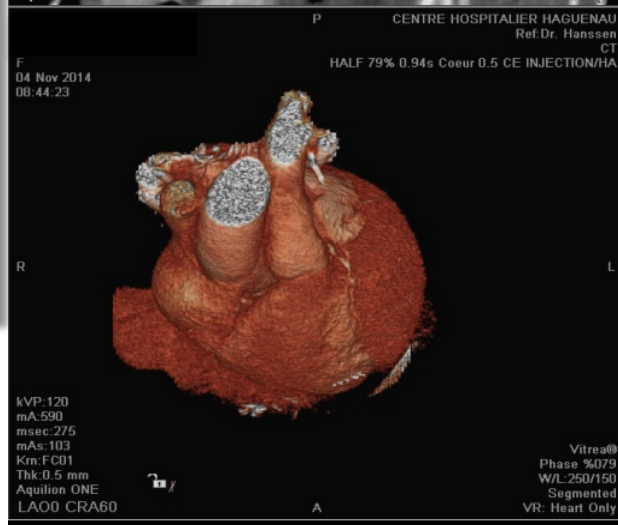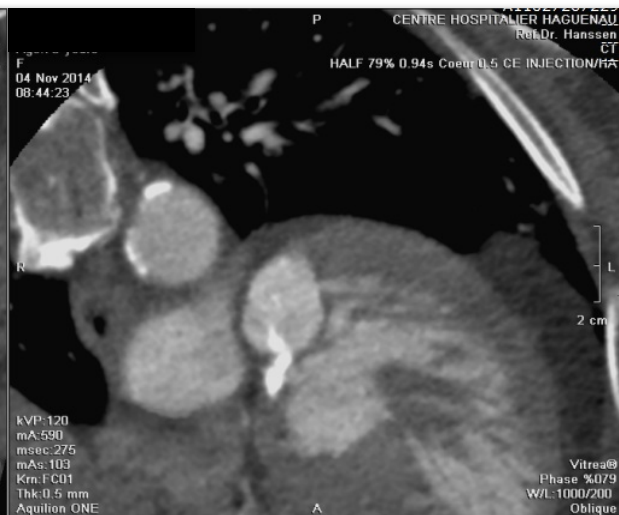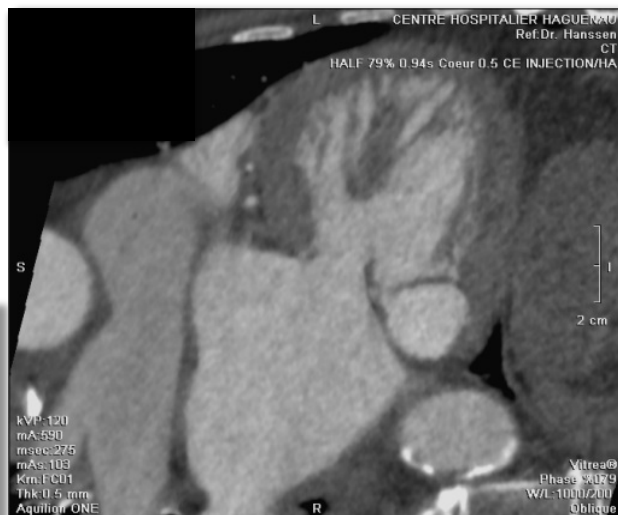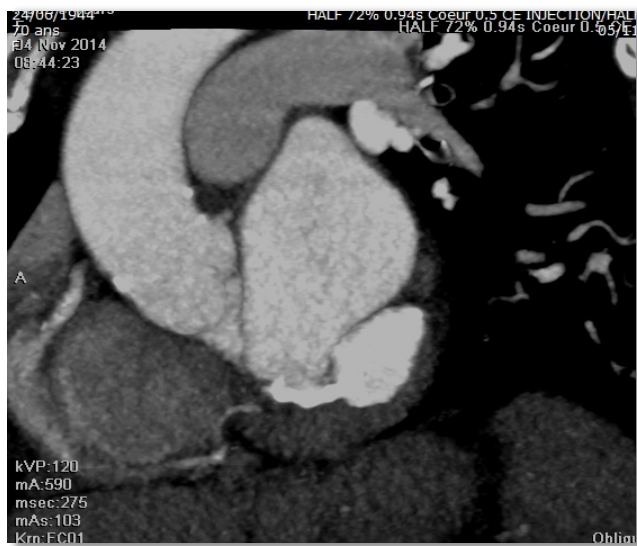


SCANNER CARDIAC

HALF 72% 0.94s Coeur 0.5 CE INJECTION / HALF 72% CFA FC  
HALF 79% 0.94s Coeur 0.5 CE INJECTION / HALF 72% CFA FC  
A11027267229

R  
2 cm

Z: 1  
Vr:144  
W:225  
Phase %87.5  
W/L:1000/200  
OR:18  
Oblique



## Au total

- Masse dans le sillon AV,
- Pas de retentissement sur la valve mitrale,
- Non vascularisée,
- Calcifications périphériques marquées,
- Contenu liquidien.

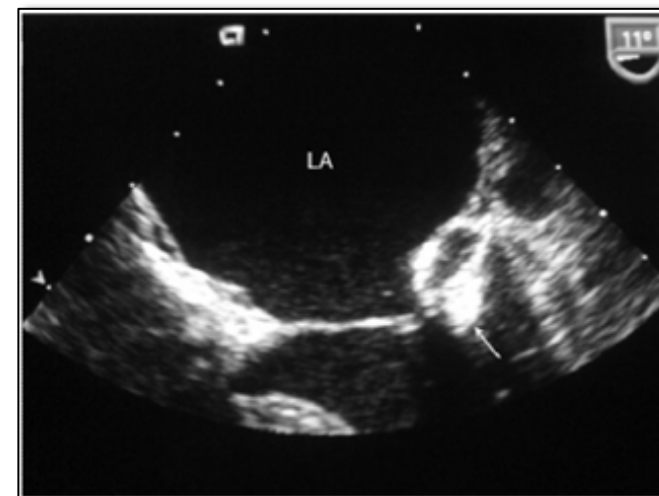
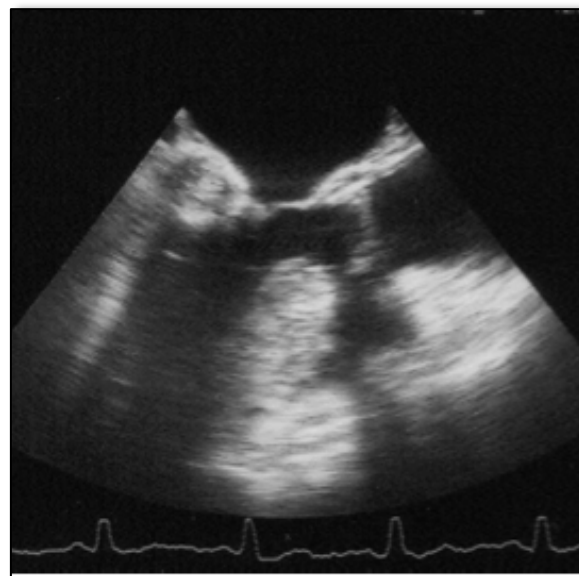
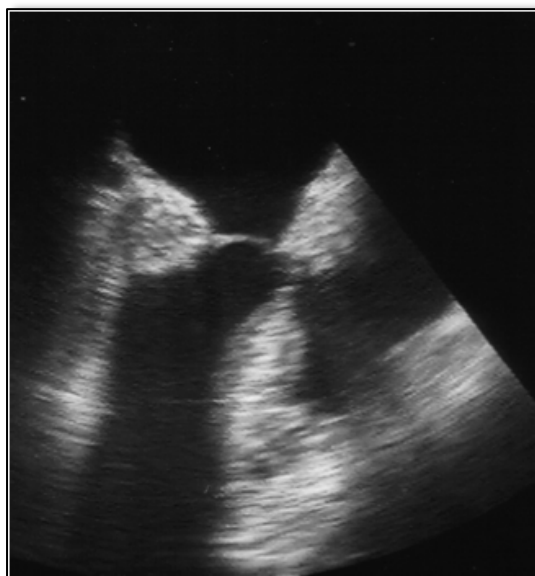
# CAT?

- Autres examens d'imagerie?
  - PET Scan
  - Scinti MIBG
- Biopsie chirurgicale/Anapath?
- CI à la prise en charge néoplasique jusqu'à nouvel ordre?

# Liquéfaction «caséuse» de calcification mitrale

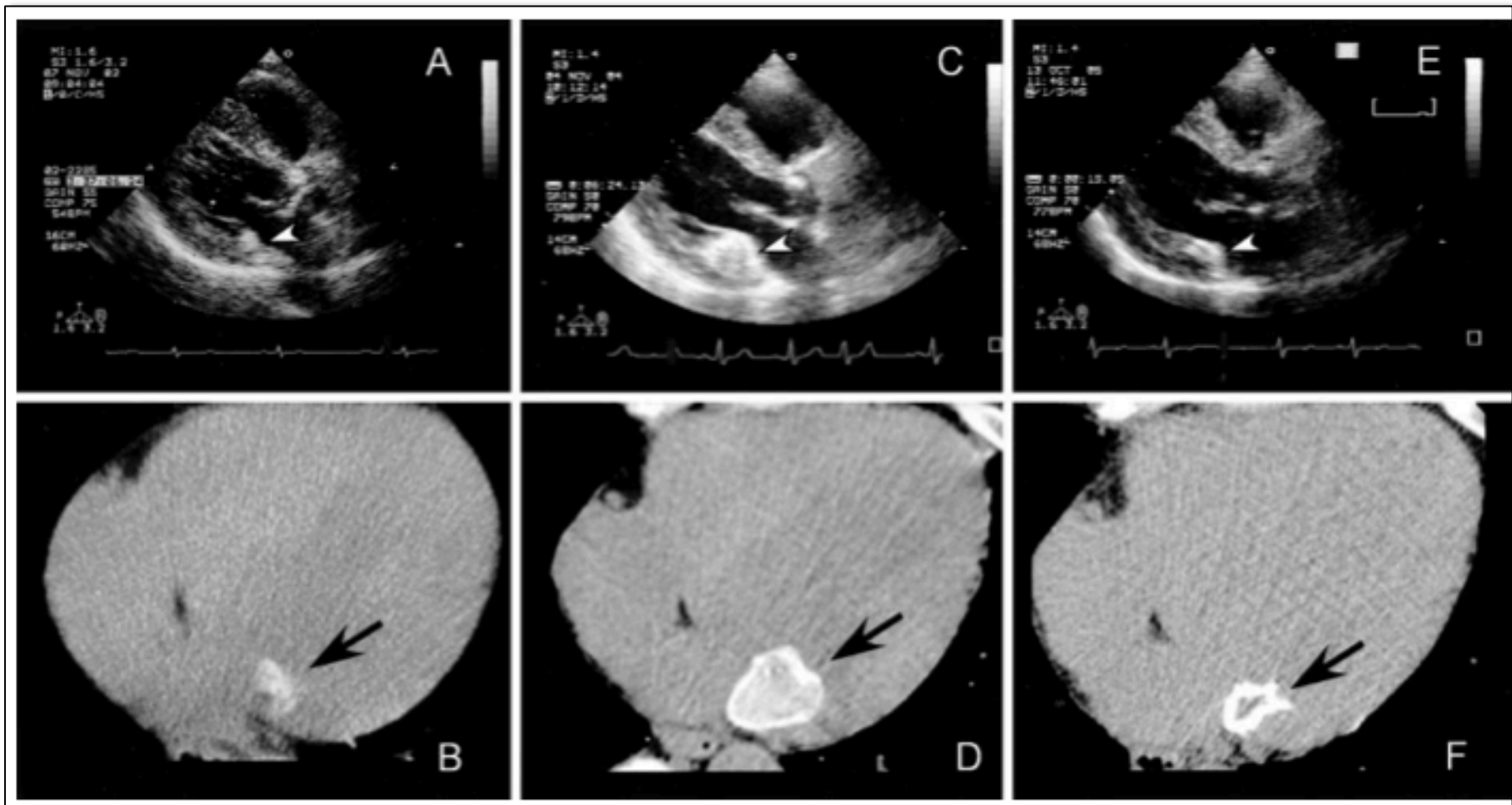
- Prévalence mal connue estimée à 0.067% de la population et 0.63% des patients avec calcifications de l'anneau,
- Femmes âgées, patients insuffisants rénaux,
- Nécrose des calcifications mitrales,
- **Masse à centre liquidien et à paroi fibreuse**  
+/- calcifiée
- Mécanisme mal connu : processus dynamique, allant d'une masse solide à la liquéfaction puis régression voire disparition.



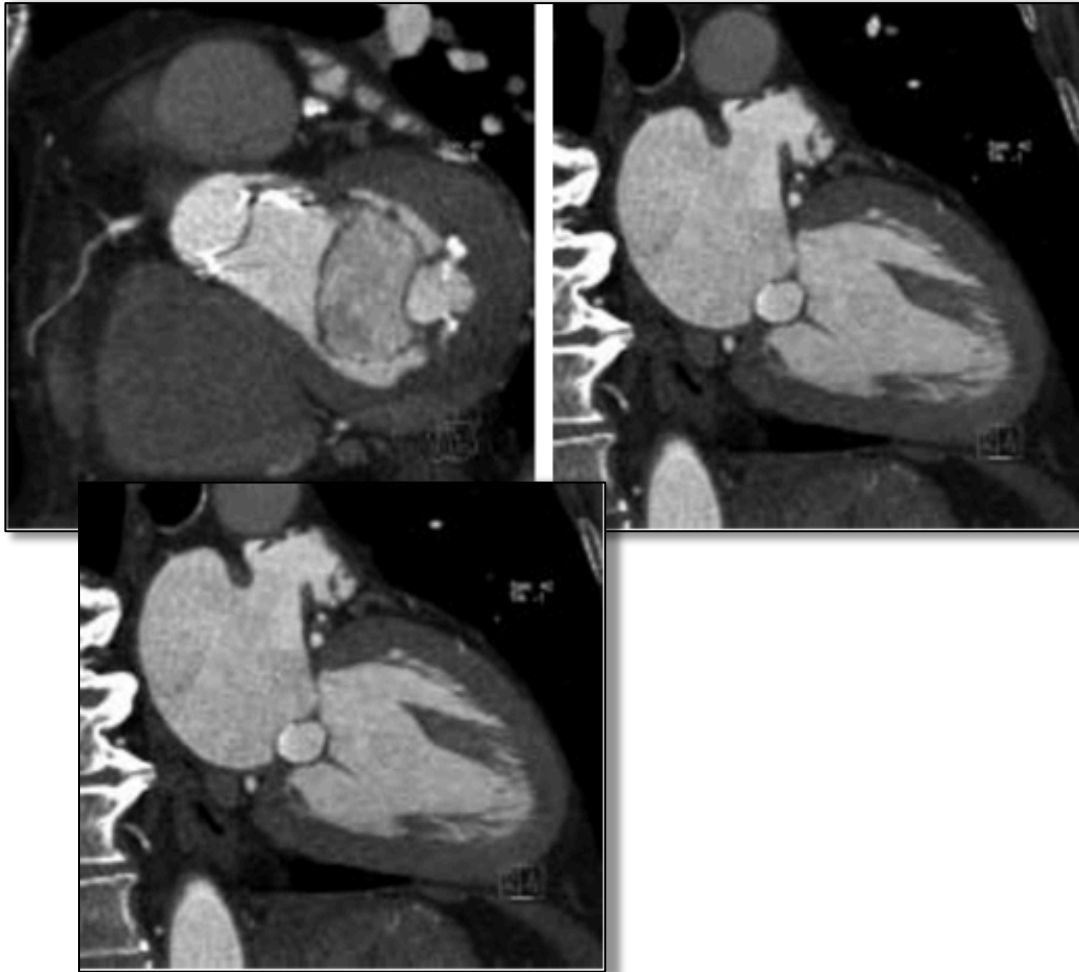


- Masse ronde échogène pleine, située dans le sillon AV et le mur myocardique latéral,
- Bords réguliers,
- Pas de cône d'ombre.

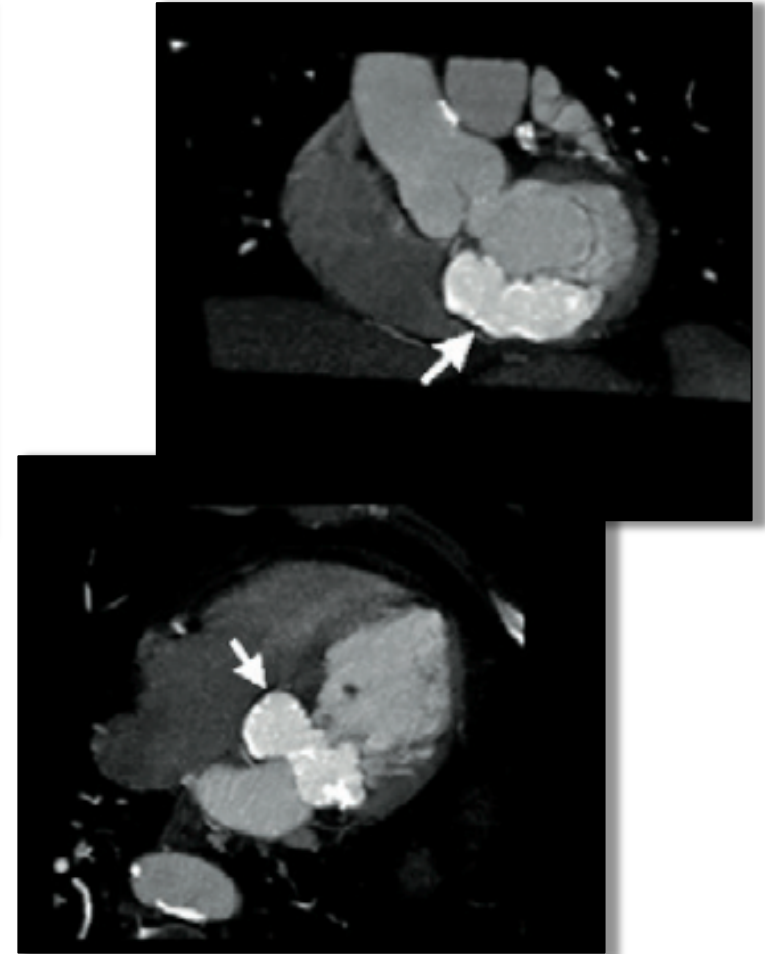
Harpaz, J Am Soc Echocardiogr 2001;14:825-31



Yokoyama, *Circulation*. 2007;115:e1-e2

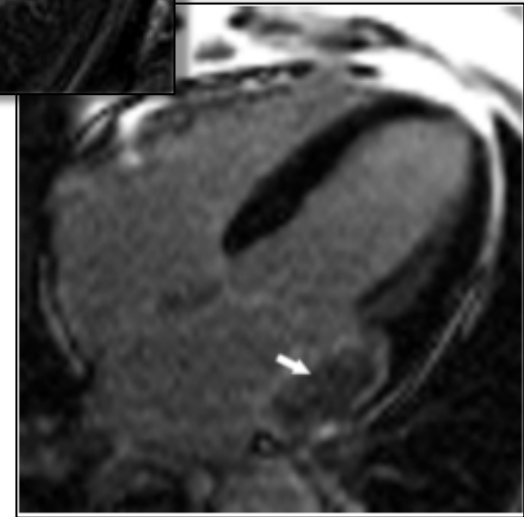
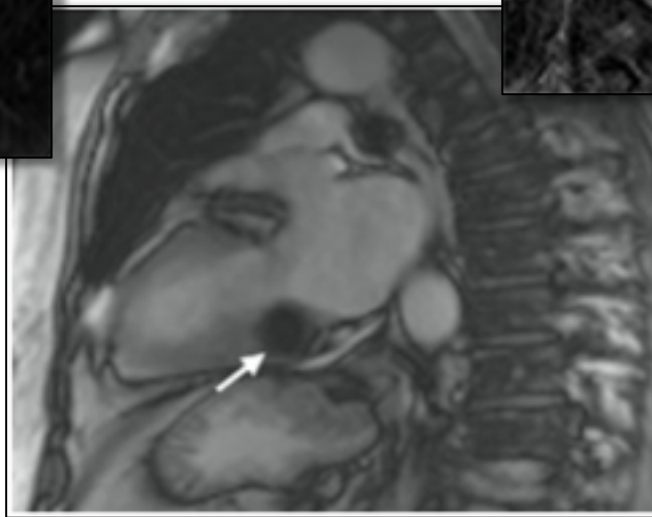
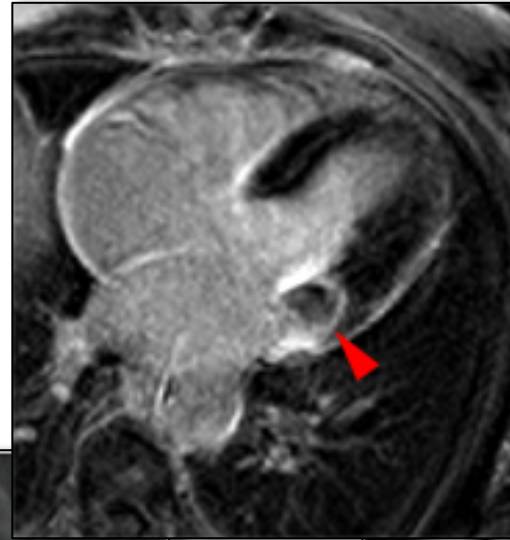
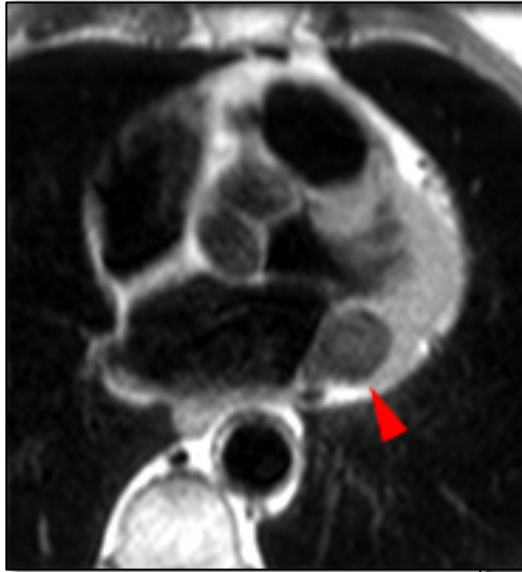


Pouliquen, J Radiol 2009;90:597-604



Ribeiro, Rev Port Cardiol. 2012;31(4):313-316





Ribeiro, Rev Port Cardiol. 2012;31(4):313-316

Chen, Circulation. 2012;125:2792-2795