

15<sup>e</sup> édition [www.appac.fr](http://www.appac.fr)

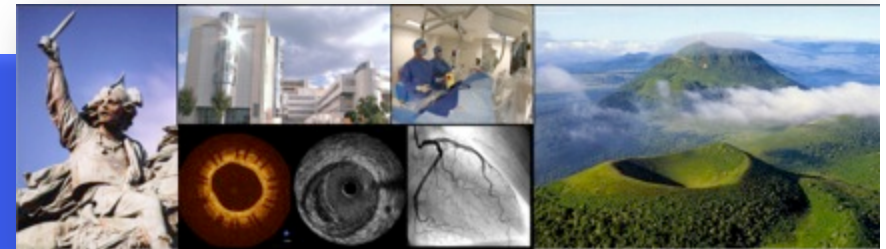BIARRITZ 5-6 ET 7 JUIN 2013

APPAC

ACTUALISATIONS ET PERSPECTIVES  
EN PATHOLOGIE CARDIOVASCULAIRE



Clermont-Ferrand



# Stentys

## La preuve par l'image

Géraud SOUTEYRAND, Pascal MOTREFF



Conflits d'intérêts : consultant St-Jude médical, Terumo





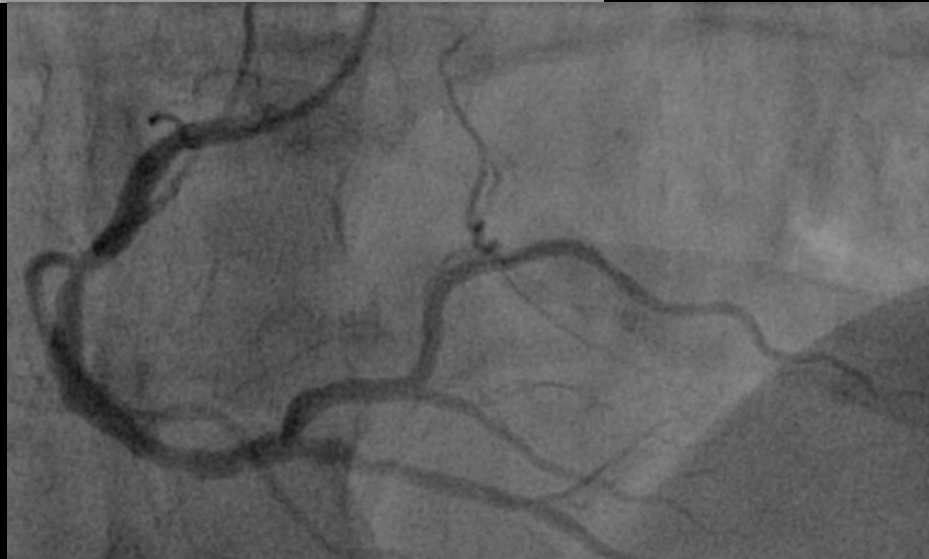## Apposition 4

**Mr M. , 63 ans**

**Dyslipidémie**

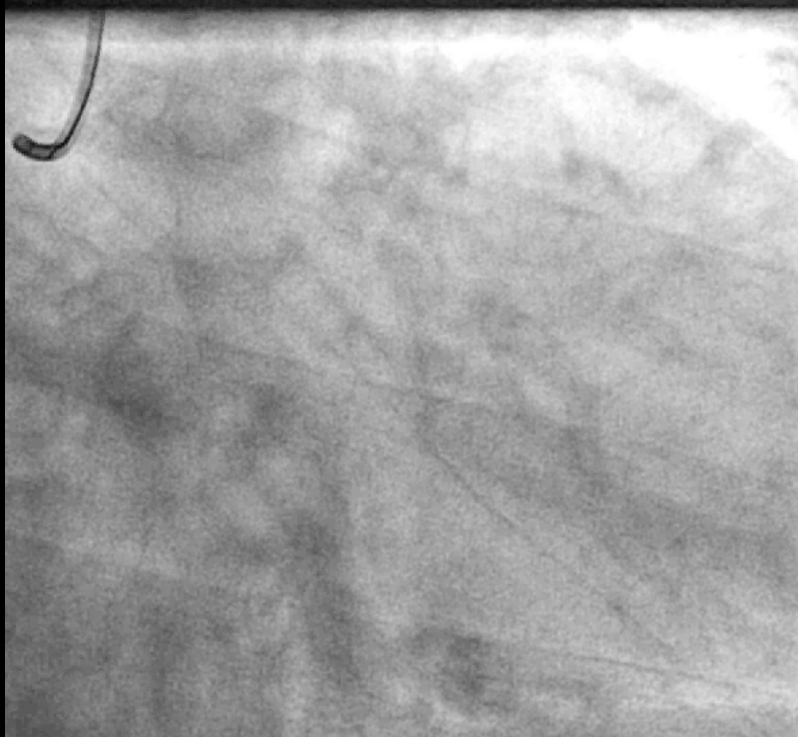
**SCA ST+ latéral H+2**

**reperfusion a l'arrivée en salle**



## Apposition 4

**Mr M. , 63 ans**  
**Réseau gauche**



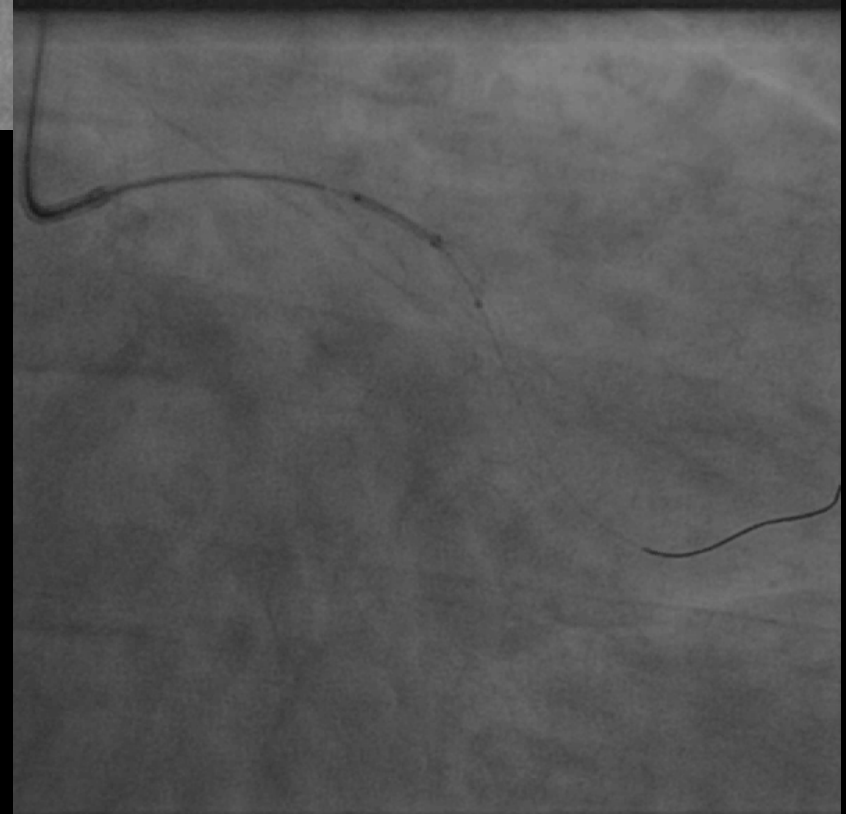
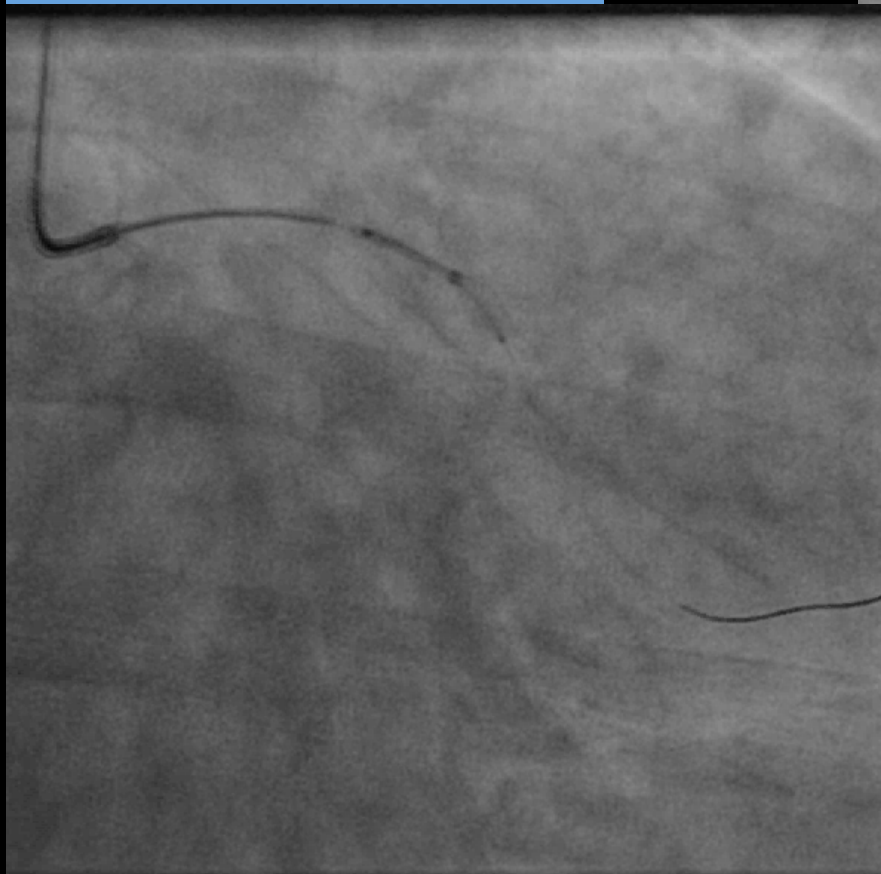
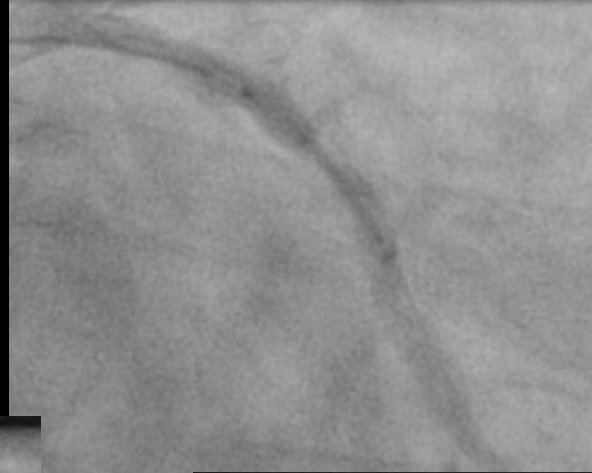
**Randomisé**  
**Groupe Stentys**



# Apposition 4

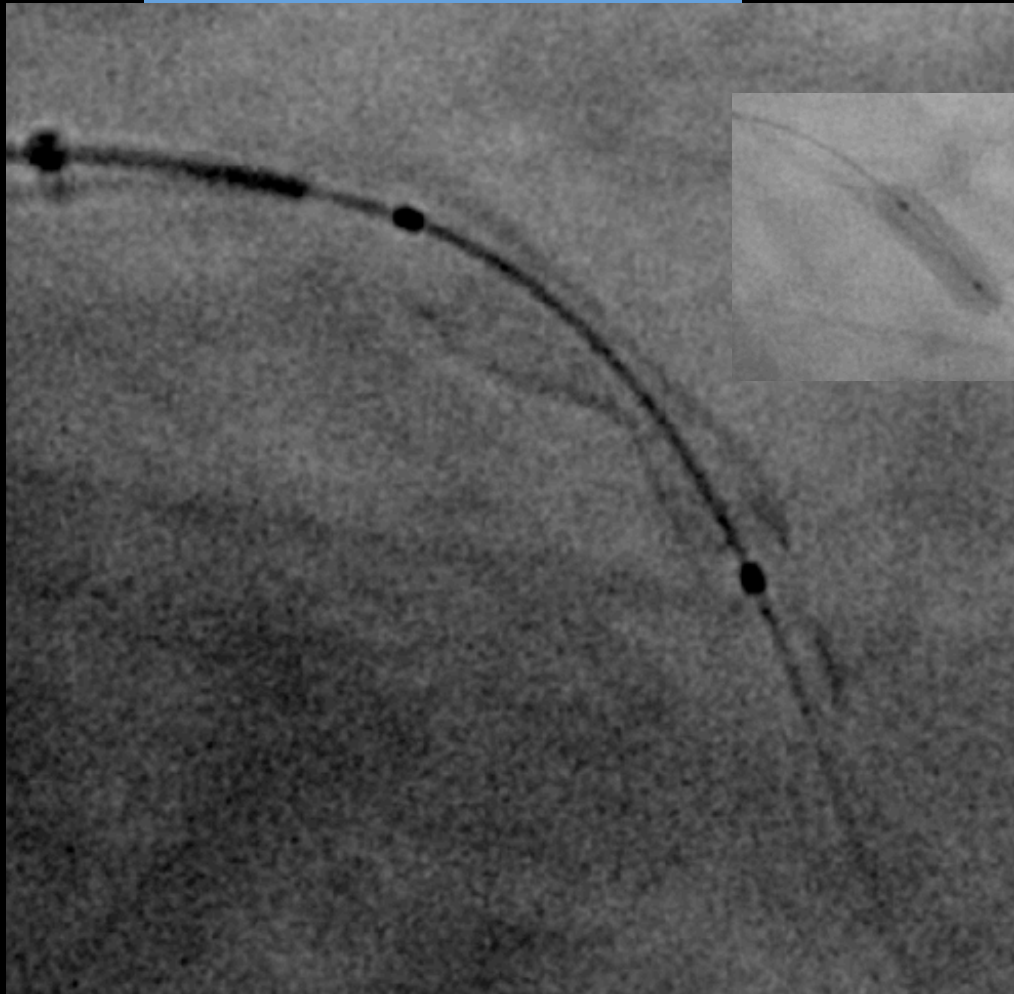
# Positionnement

# Retrait gaine

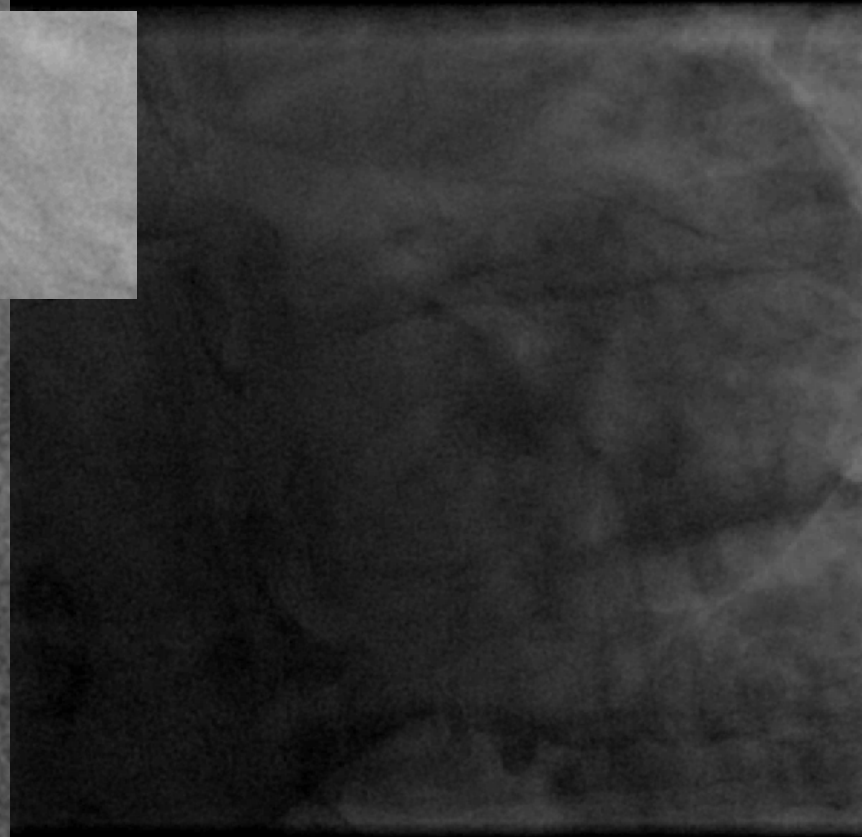
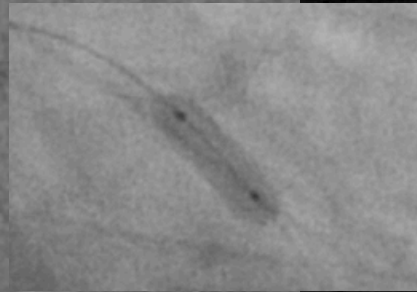


# Apposition 4

Résultat

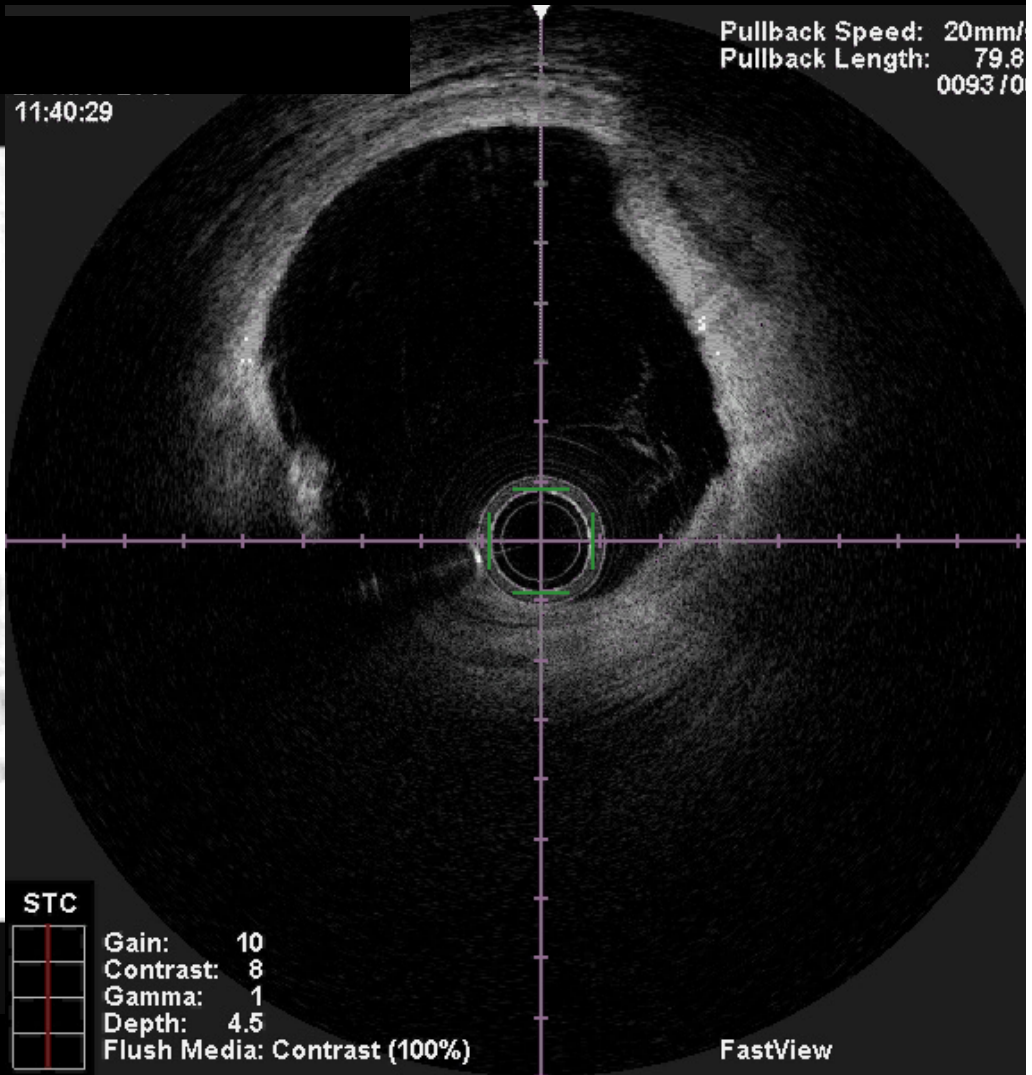
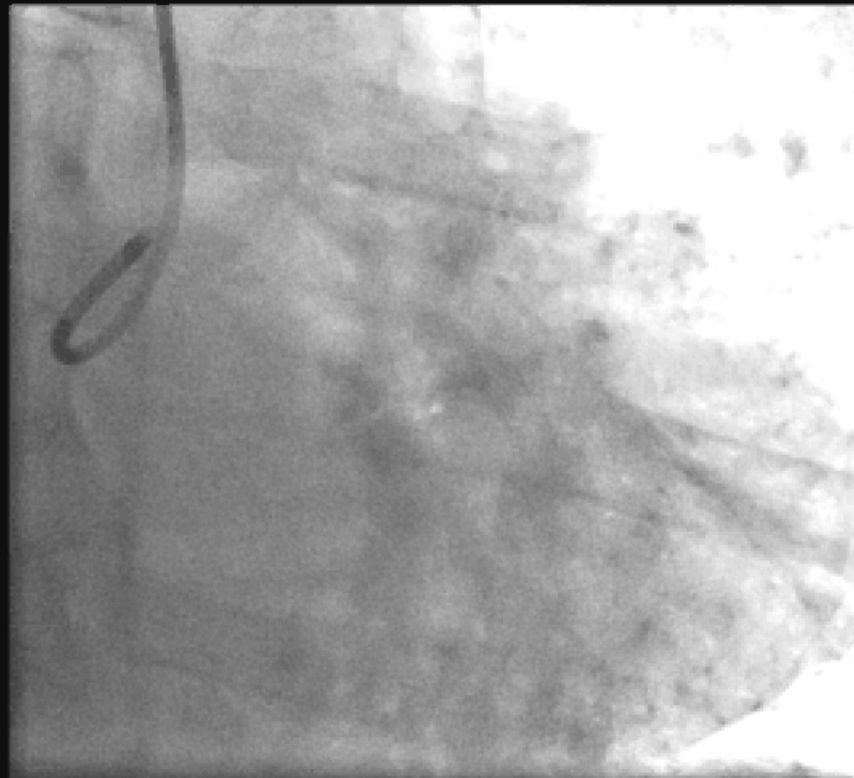


Post-dilatation

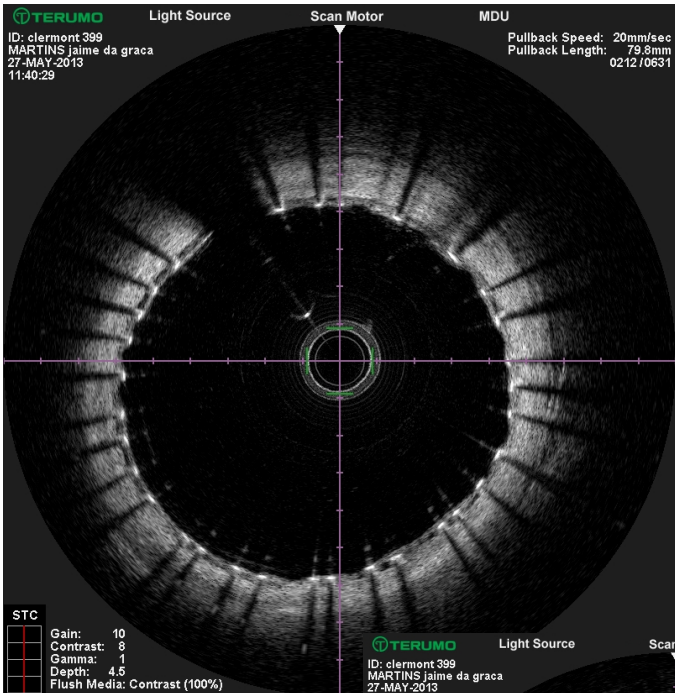


# Apposition 4

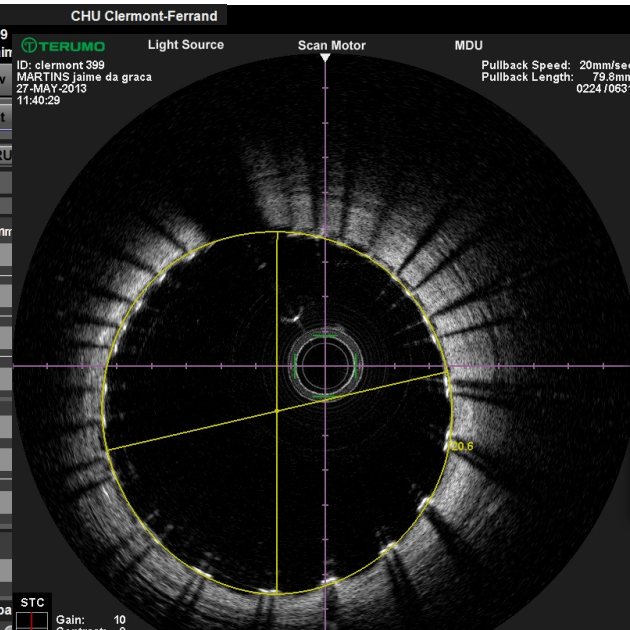
# Randomisé contrôle 4 mois





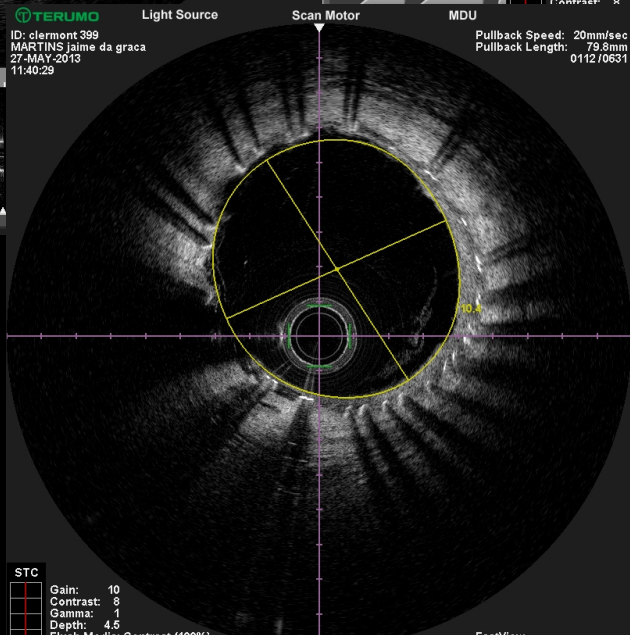
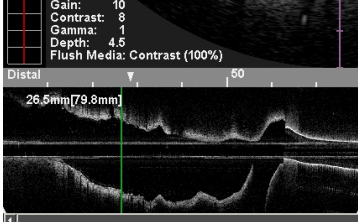


Patient ID: clermont 399  
 Patient Name: MARTINS Jaime da graca  
 Case Data Review  
 Patient Info SetPoint  
 RUN2  
 Axial Area(mm<sup>2</sup>)  
 Lumen  
 Vessel  
 Stent  
 Other  
 Distance(mm)  
 Angle(°)  
 Longitudinal Length(mm)  
 Playback STC



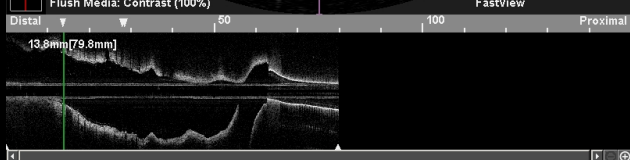
CHU Clermont-Ferrand  
 Patient ID: clermont 399  
 Patient Name: MARTINS Jaime da graca  
 Case Data Review File Setting  
 Patient Info SetPoint Description Measure  
 RUN2 RUN1  
 Axial Area(mm<sup>2</sup>) Max.Dia(mm) Min.Dia(mm)  
 Lumen 20.6 5.22 5.03  
 Vessel  
 Stent  
 Longitudinal Length(mm)  
 Playback Control  
 Speed 1/8 1/4 1/2 1x 2x  
 Bookmark Bookmark Tab  
 Zoom 1x Finish  
 27 - MAY - 2013 11:47 HDD Logoff

**5.2x5.0**



CHU Clermont-Ferrand  
 Patient ID: clermont 399  
 Patient Name: MARTINS Jaime da graca  
 Case Data Review File Setting  
 RUN1 RUN2  
 File Search Run Description Measure  
 Axial Area(mm<sup>2</sup>) Max.Dia(mm) Min.Dia(mm)  
 Lumen 10.4 3.77 3.46  
 Vessel  
 Stent  
 Other  
 Distance  
 Angle  
 Longitudinal Length(mm)  
 Playback Control  
 Speed 1/8 1/4 1/2 1x 2x  
 Bookmark Bookmark Tab  
 Zoom 1x Finish  
 29 - MAY - 2013 13:07 HDD Logoff

**3.7x3.4**







# Le stent auto-apposant STENTYS<sup>®</sup>

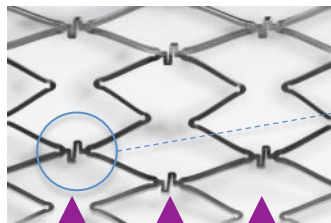
Technique

Intérêts

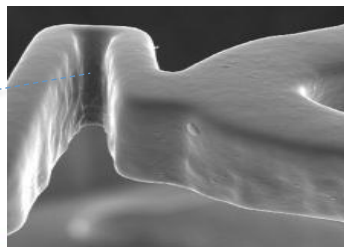
Résultats



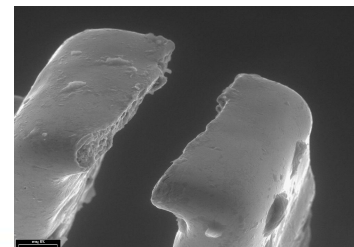
- Stent auto-expansible en nitinol déployé par retrait d'une gaine de protection (sans ballonnet)
- Stent nu ou à élution de Paclitaxel avec polymère durable
- Compatible 6F à échange rapide
- Déconnexion des mailles sur toute la longueur\* pour un accès aux branches latérales




Déconnecteurs



Déconnecteurs



Déconnexion



\* Except the first and last 2mm

15<sup>e</sup> édition [www.appac.fr](http://www.appac.fr)

BIARRITZ 5-6 ET 7 JUIN 2013

APPAC

ACTUALISATIONS ET PERSPECTIVES  
EN PATHOLOGIE CARDIOVASCULAIRE



## Pourquoi un stent auto-expandable?





15<sup>e</sup> édition [www.appac.fr](http://www.appac.fr)

BIARRITZ 5-6 ET 7 JUIN 2013

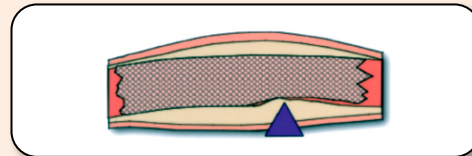
APPAC

ACTUALISATIONS ET PERSPECTIVES  
EN PATHOLOGIE CARDIOVASCULAIRE

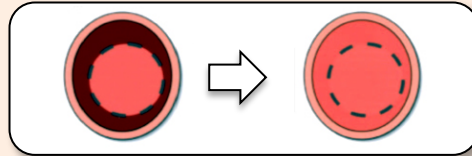


Dans notre pratique

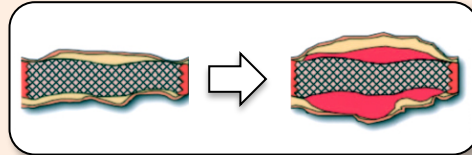
Améliorer apposition



Sous-déploiement initial



Détersion de thrombus



Remodelage positif

*S. Cook, Circulation. 2007;115:2426-2434*



# Le stent auto-apposant STENTYS<sup>®</sup>

Technique

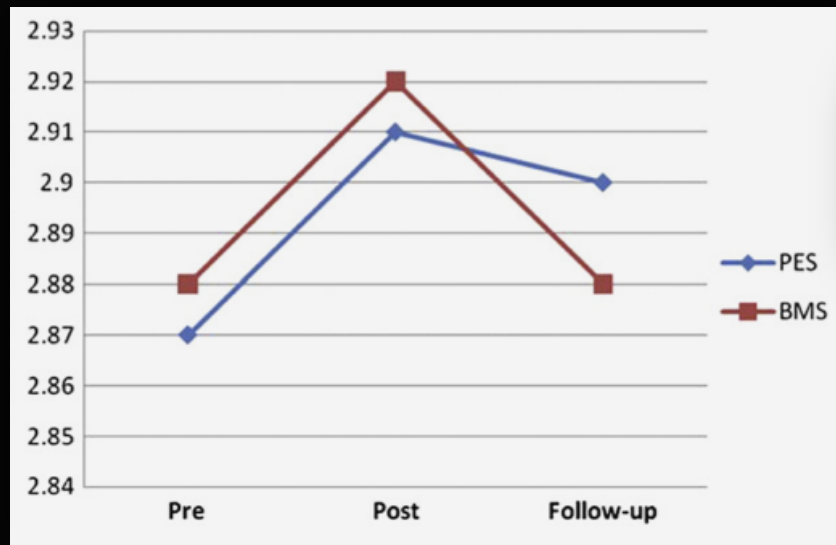
Intérêts

Résultats

Malapposition

## Etude HORIZONS

1197 patients ont eu suivi angio  
Suivi moyen 11 mois



RVD	Pre-PCI	Post-PCI	Follow-up
All (PES+ BMS) (mm)	2.88 (2.54-3.22)	2.94 (2.59-3.27)	2.88 (2.55-3.22)
PES (mm)	2.88 (2.53-3.24)	2.93 (2.57-3.27)	2.88 (2.55-3.22)
BMS (mm)	2.91 (2.59-3.17)	2.95 (2.63-3.27)	2.88 (2.57-3.22)
P (PES vs BMS)	.81	.54	.72

Pas de différence significative





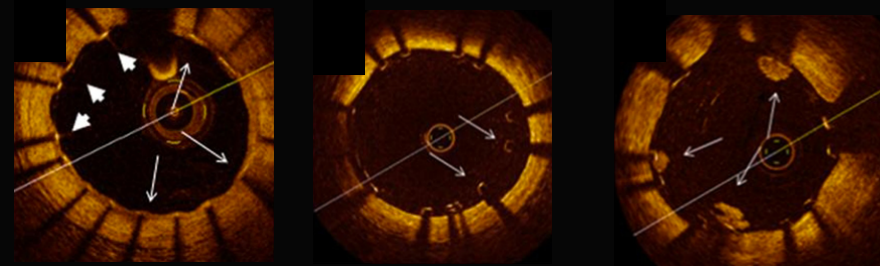
## Registre DETECTIVE

OCT 3 à 7 jours après stenting phase aiguë

15 patients, 28 stents

64% stents sur lésion coupable, 36% non-coupable

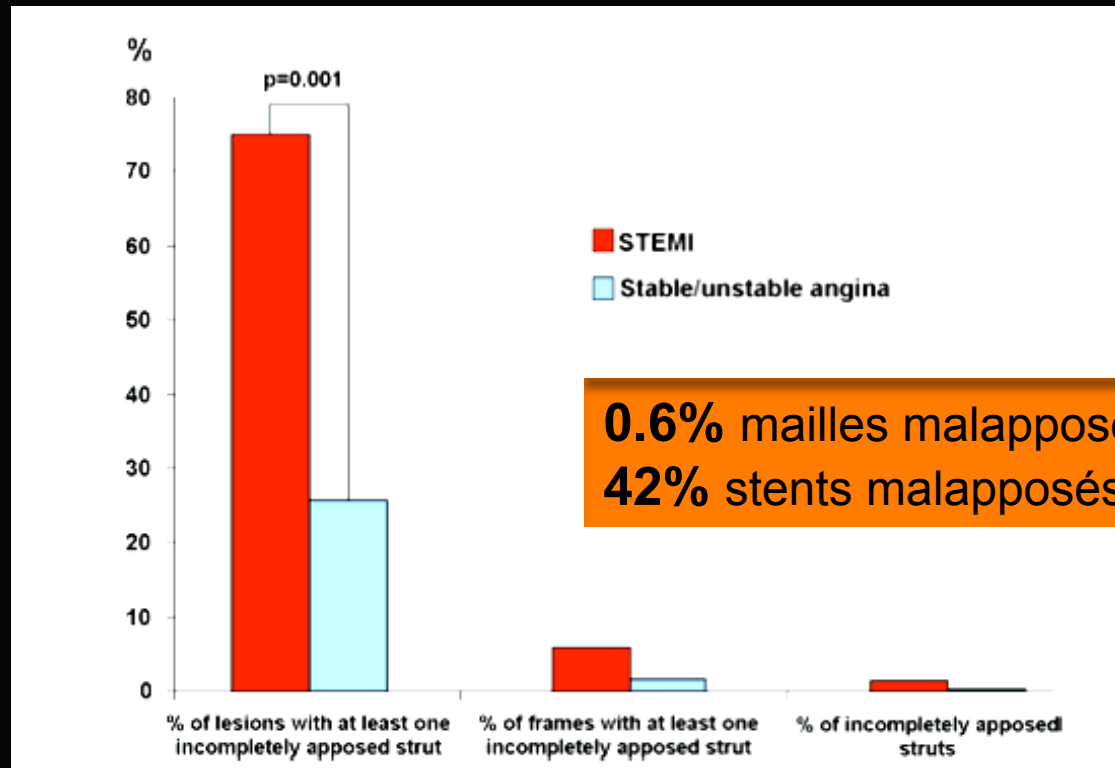
	Total struts (n)	Uncoverage		Malapposition		Thrombus coverage	
		n	%	n	%	n	%
DES	11 547	1479	12.8	556	4.8	351	3.0
CCS	15 463	1680	10.9	732	4.7	253	1.6
Stents in culprit lesions	17 868	2360	13.2	1126	6.3	550	3.1
Stents in non-culprit lesions	9142	798	8.7	163	1.8	54	0.6





## Malapposition

**43 patients traités par stents actifs (17% SCA ST-, 34% ST+)**  
**Analyse OCT à 9 mois, 10 140 mailles**

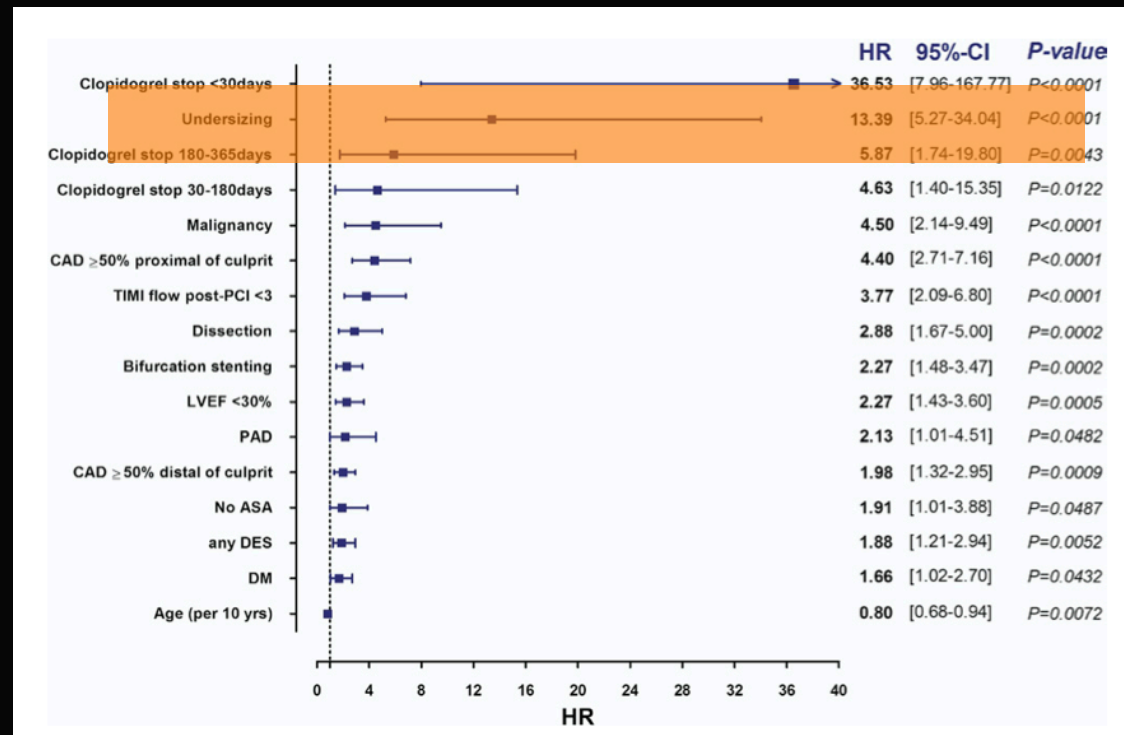




# Registre Dutch

## Malapposition

**437 patients ayant présenté thrombose de stent confirmée en angio comparés à patients ayant ATL même jour et centre sans thrombose**



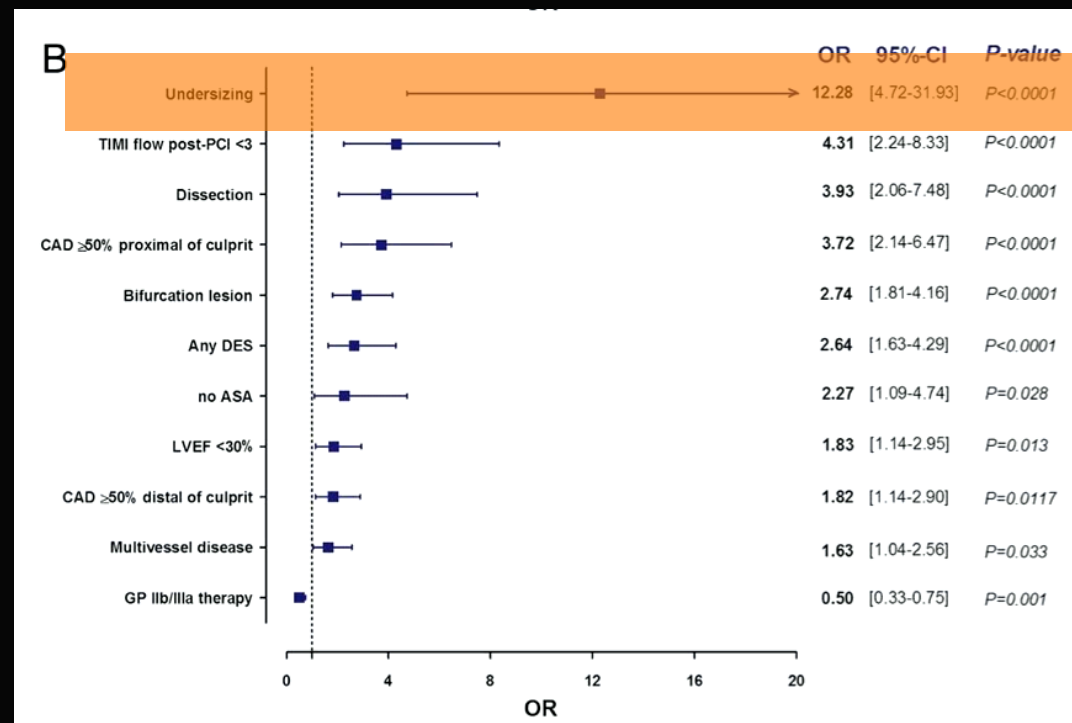


# Registre Dutch

## Intérêts

### Malapposition

## Facteurs favorisant thrombose de stent liés à la procédure Implantation lors SCA





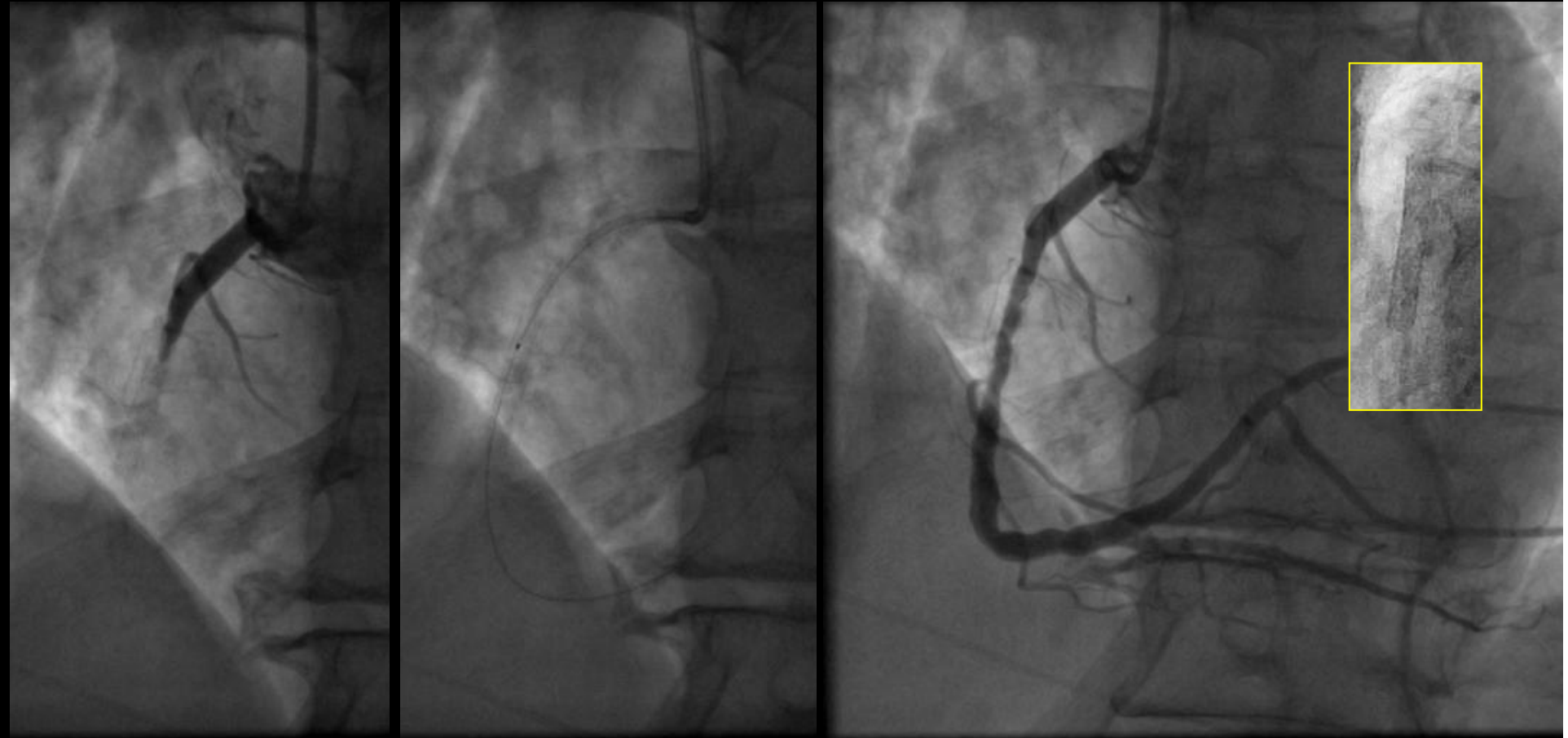
## Malapposition

**Late stent malapposition** risk is higher after drug-eluting stent compared with bare-metal stent implantation and associates with late stent thrombosis

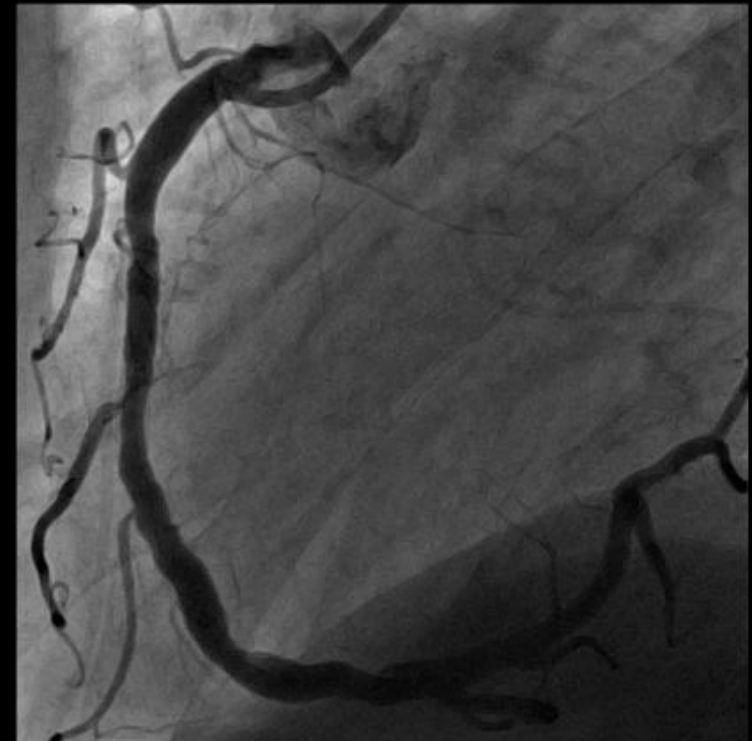
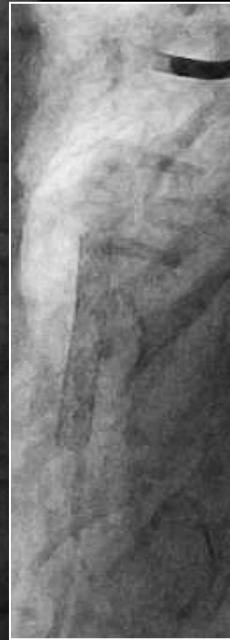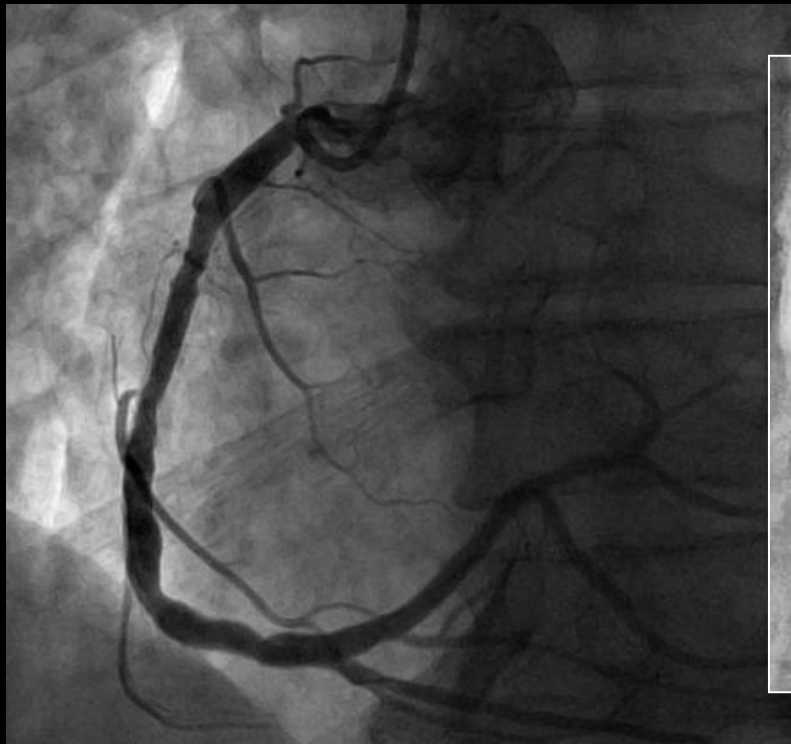**Risque de thrombose tardive x 6.5 en cas de malapposition**

*Hassan, Eur Heart J 201*

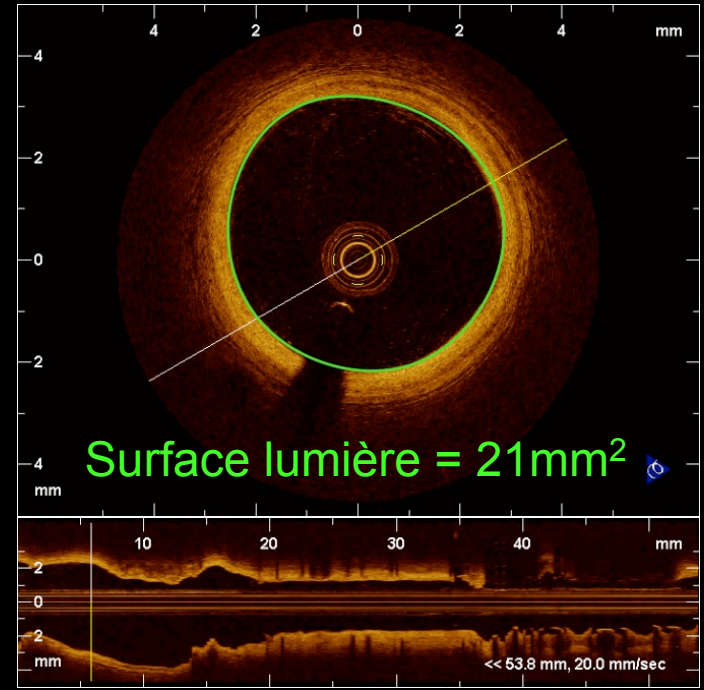
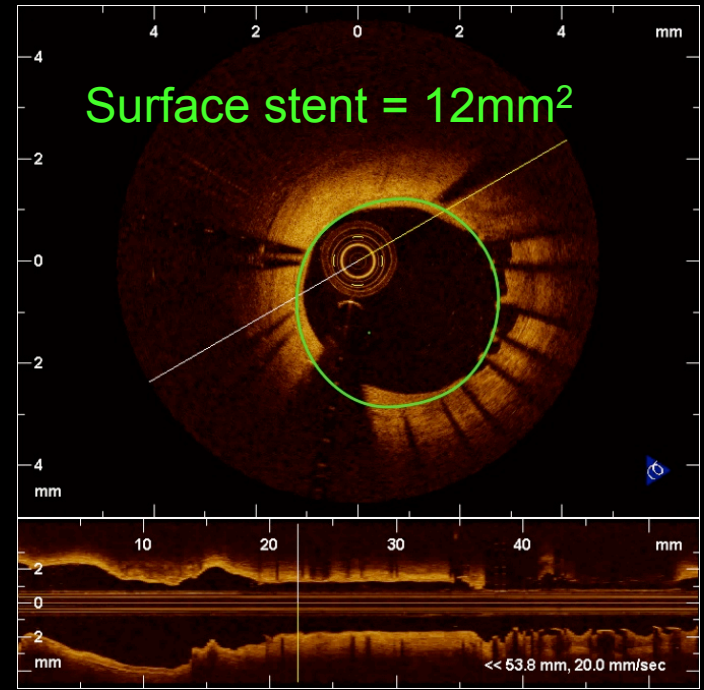
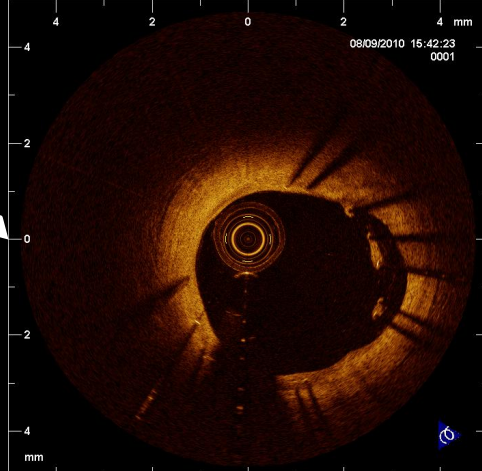
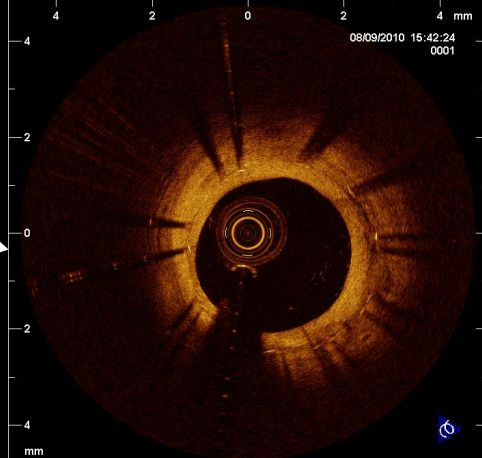
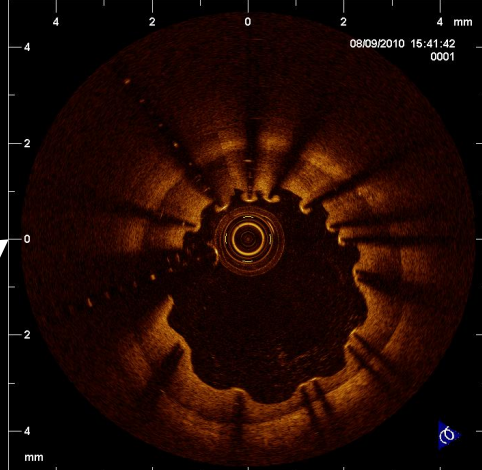
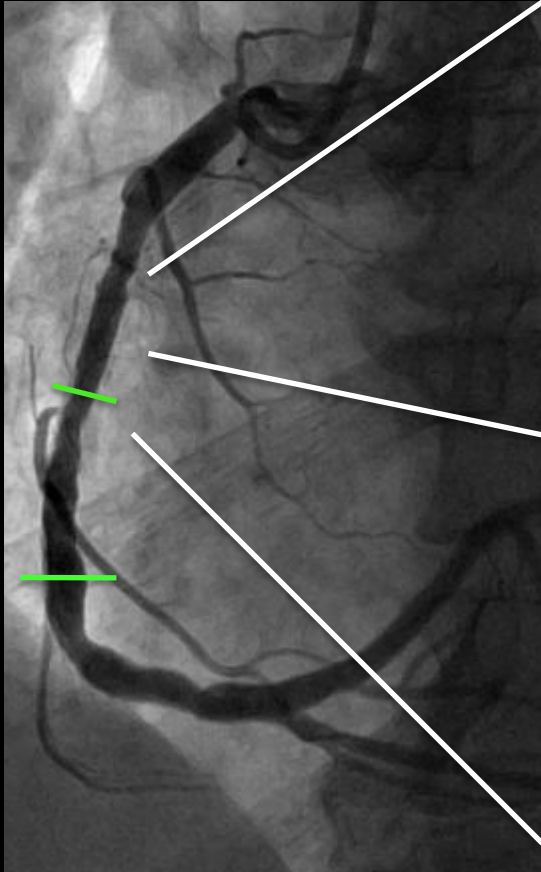
Mr H. 55 ans, SCA ST+, angioplastie primaire CD (BMS 3.5x24mm)  
5 ans plus tard... 8j après arrêt de l'aspirine  
SCA ST+ inférieur : Thrombose très tardive BMS  
Coro en phase aiguë (H1), succès de thrombo-aspiration



## Traitement médical optimal, Contrôle à 1 mois











# Evaluation taille artère

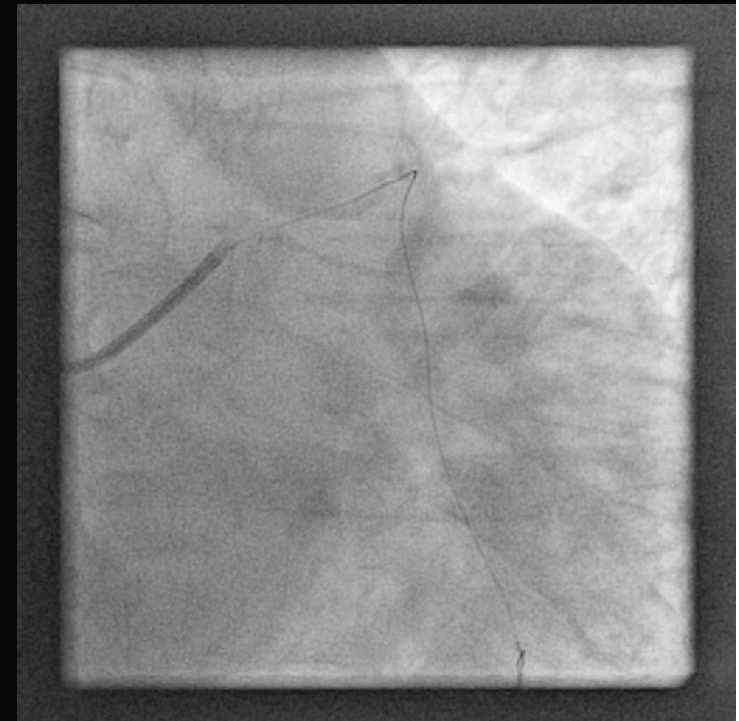
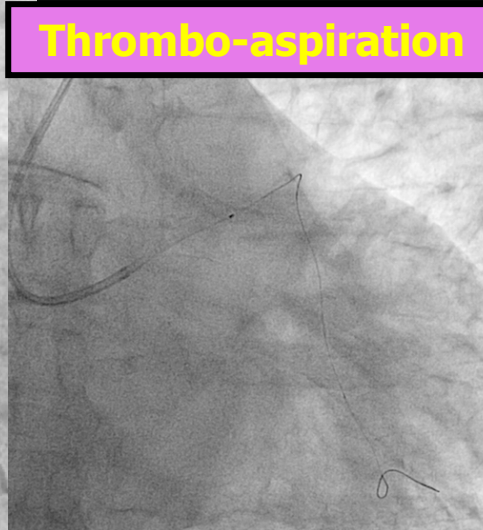
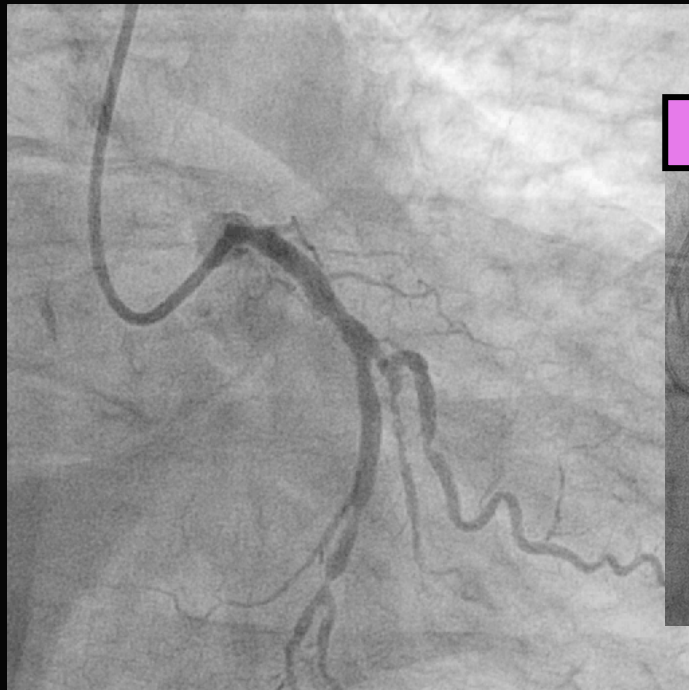
**Patient de 67 ans**

**tabagique, Diabète type 2**

**ATCD chirurgie anévrisme cérébral en 1991**

**Novembre 2011 nécrose antérieure inaugurale prise en charge à H+3**

**Hémodynamique correcte. Coro à H+4.**



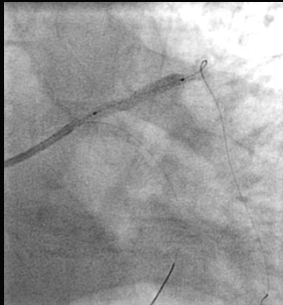
**CAT ?**  
**Quelle taille de stent??**



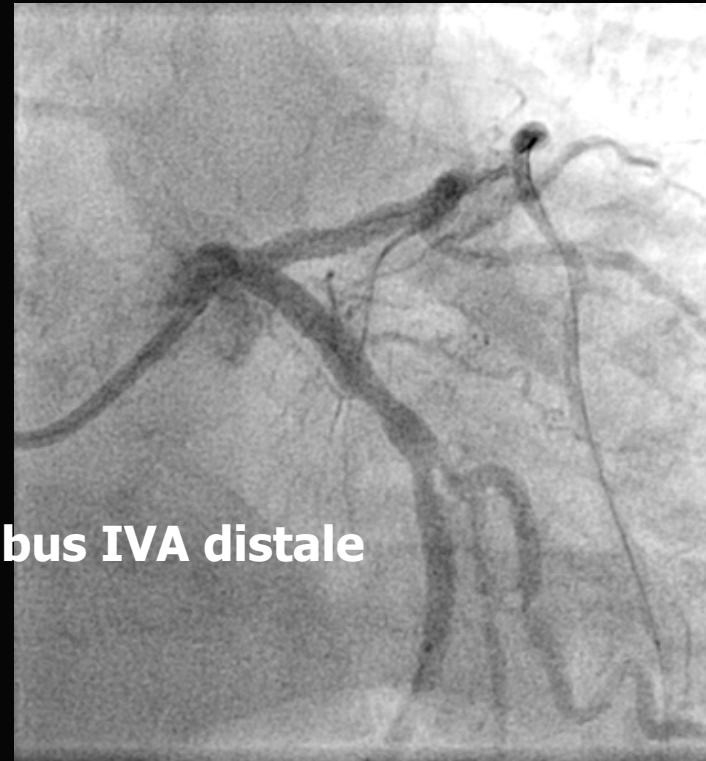
# Evaluation taille artère

## Intérêts

### Stent 3.5 x 28mm



**Evolution simple**  
**Pic CPK 3100 UI , persistance thrombus IVA distale**  
**Contrôle coro à distance**

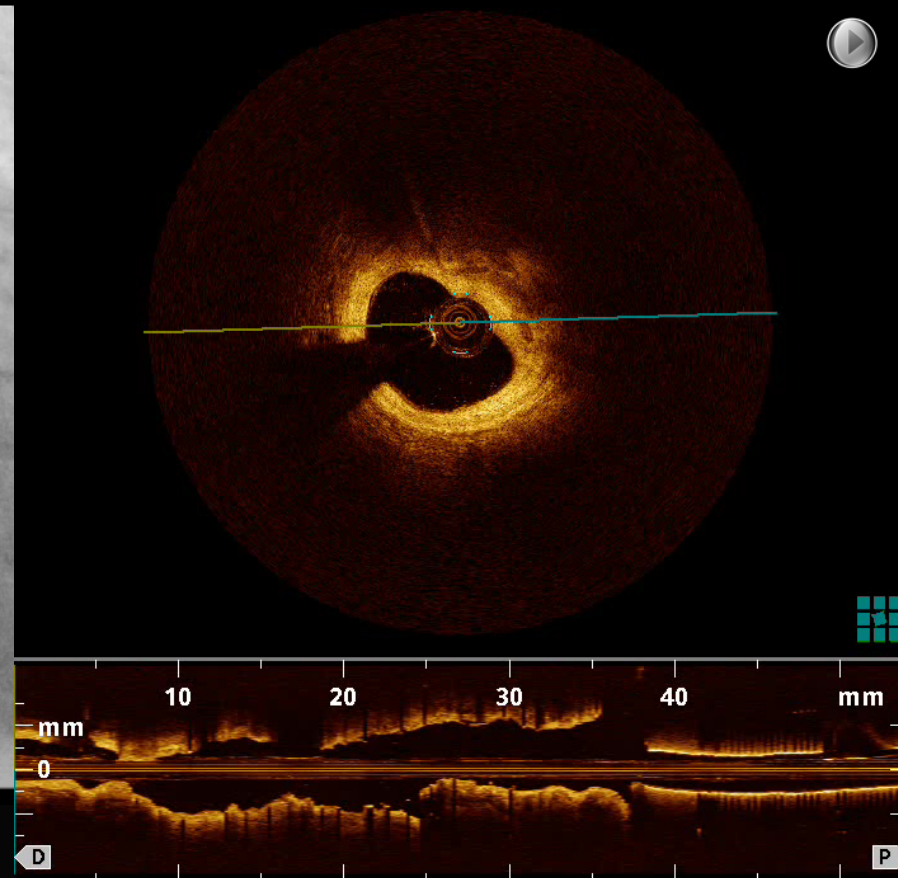
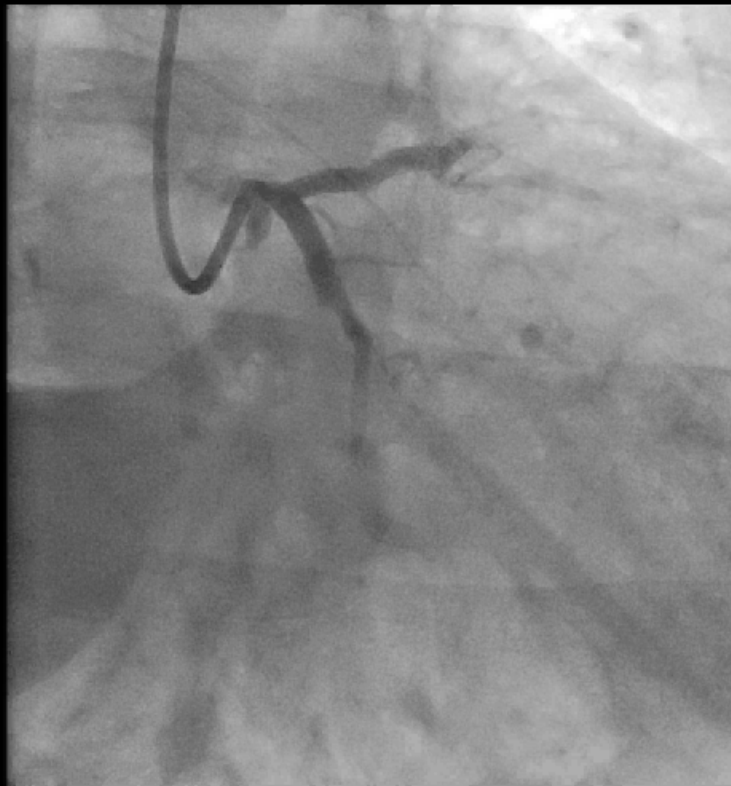




# Evaluation taille artère

**ETT FE à 50%**  
**Contrôle à J15**

Intérêts

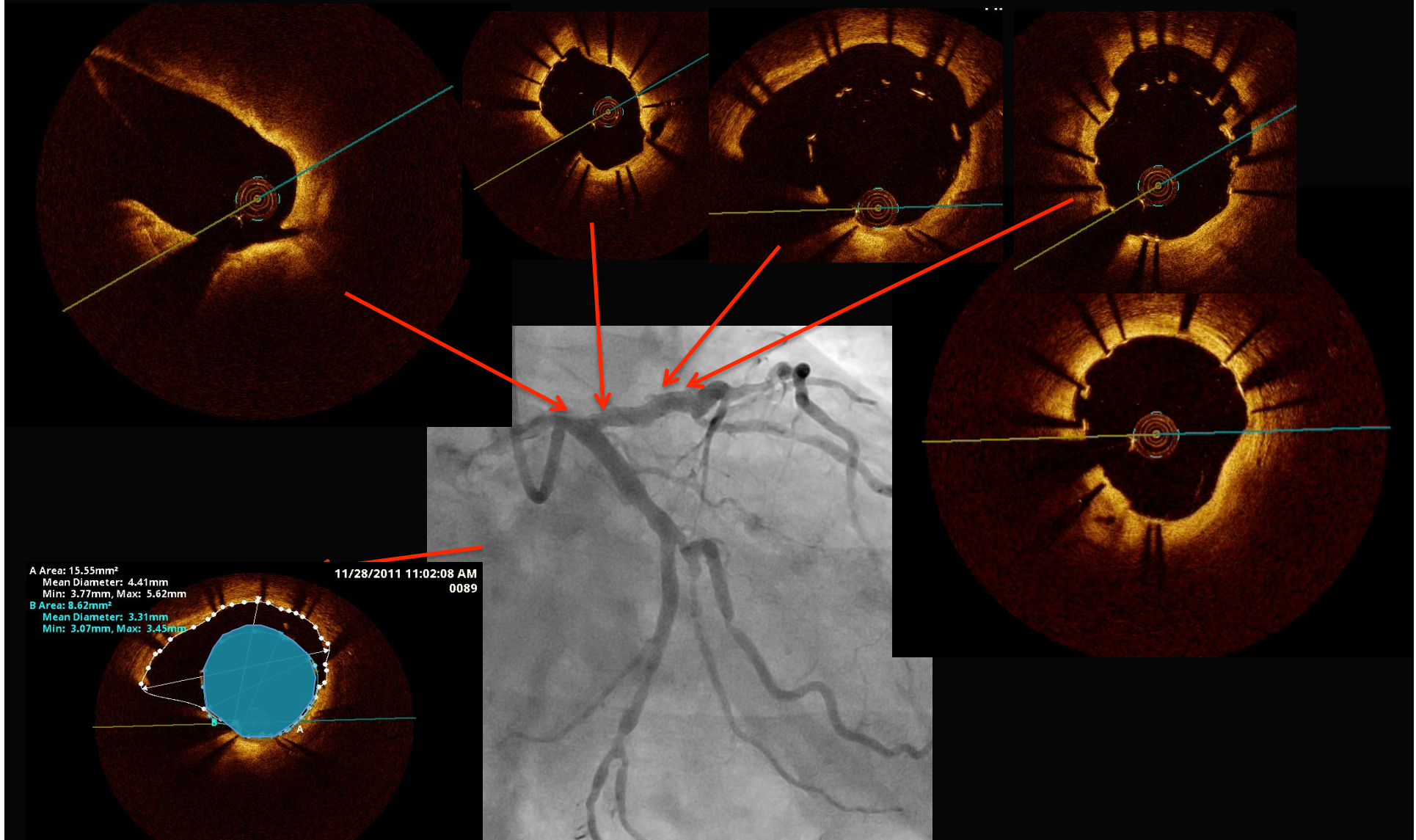






# Evaluation taille artère

## Intérêts



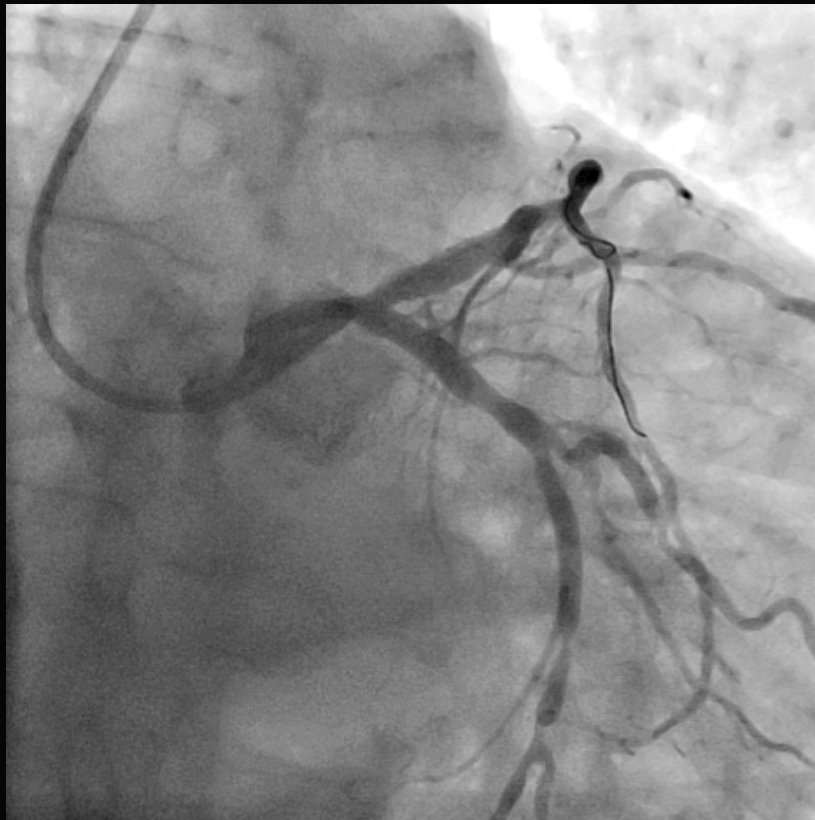




# Evaluation taille artère

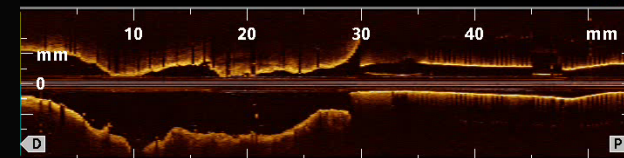
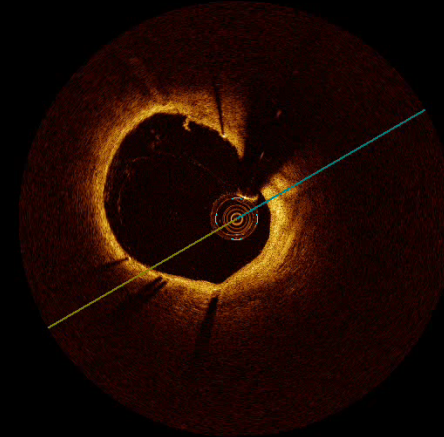
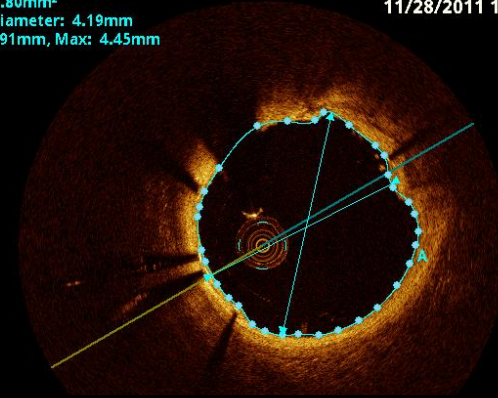
## Intérêts

### Post-dilatation ballon 4x20mm



A Area: 13.80mm<sup>2</sup>  
Mean Diameter: 4.19mm  
Min: 3.91mm, Max: 4.45mm

11/28/2011 11:24:3

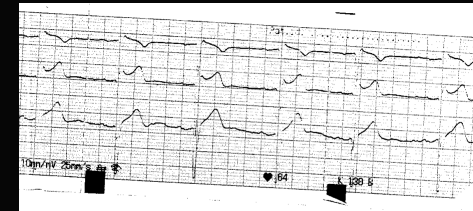




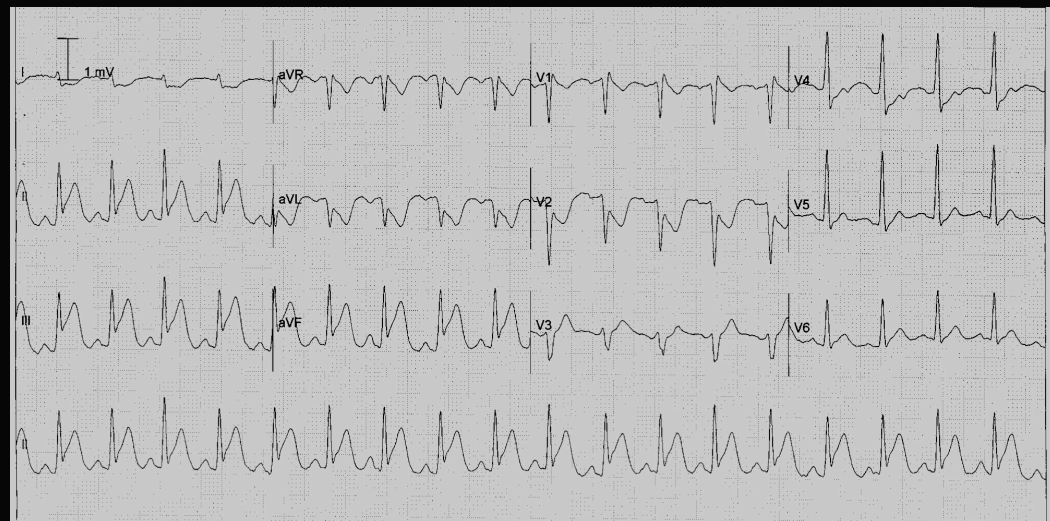
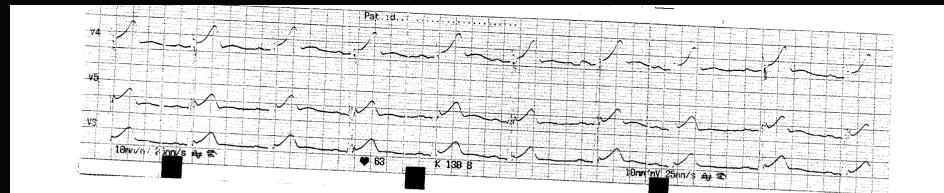
# Evaluation taille artère

## Intérêts

**Mr B. 35 ans, tabagique, HF.  
Scène infarctoire le 7/01/2013, PEC SAMU**



**Arrivée à H+2. ECG**





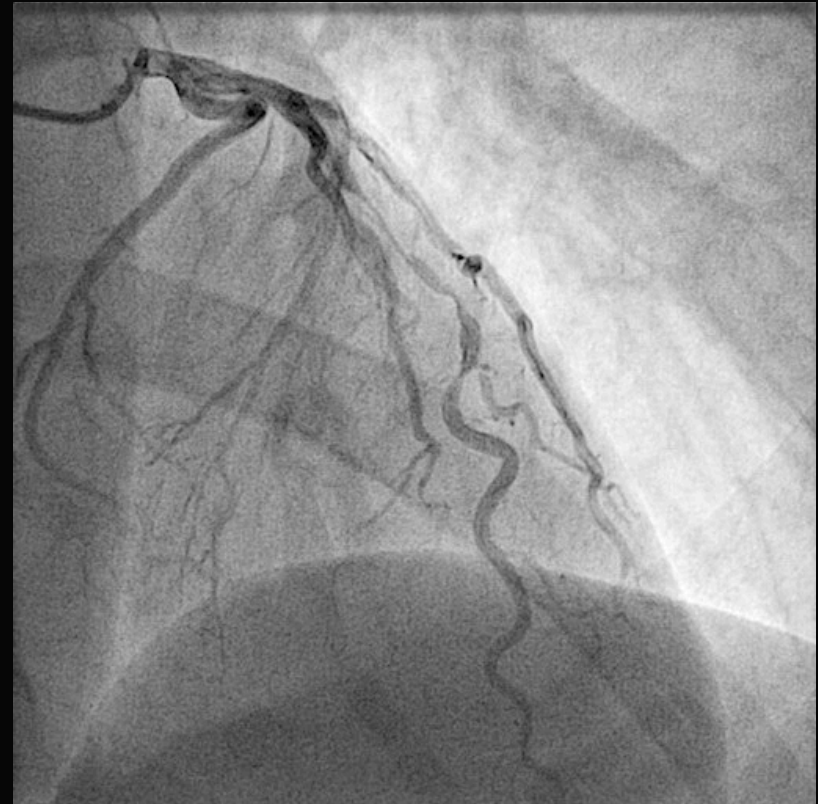
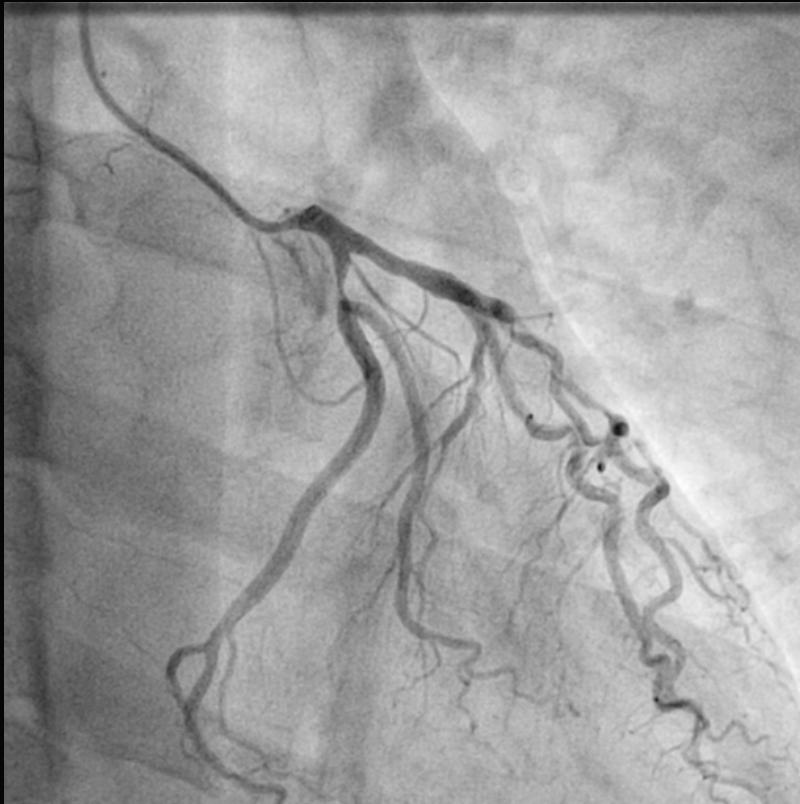# Evaluation taille artère

Technique

Intérêts

Résultats

Coronarographie



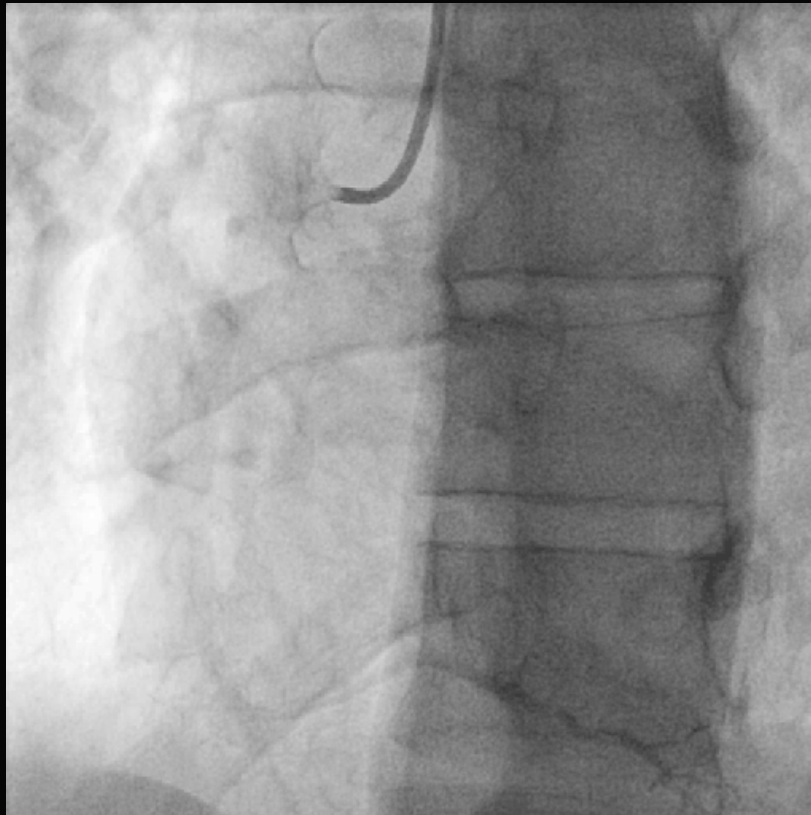




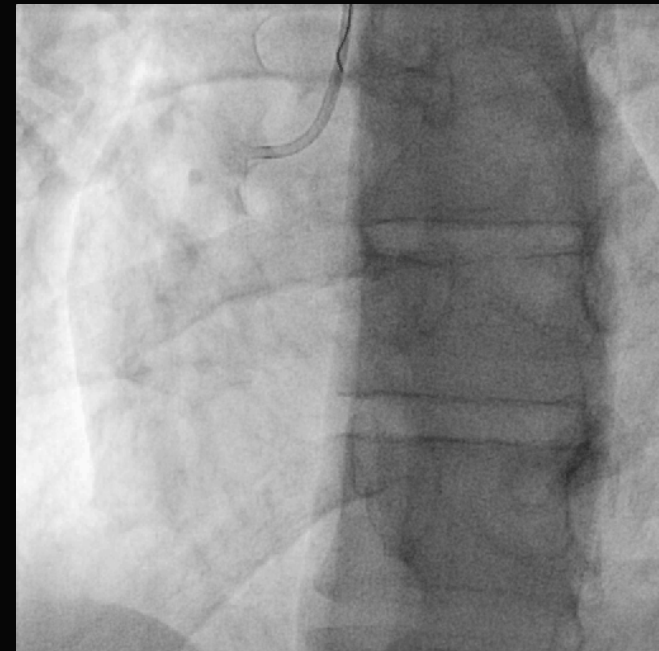
# Evaluation taille artère

## Intérêts

### Coronarographie



Lésion non levée malgré nitrés  
Stenting 3.5x18mm  
Reperfusion



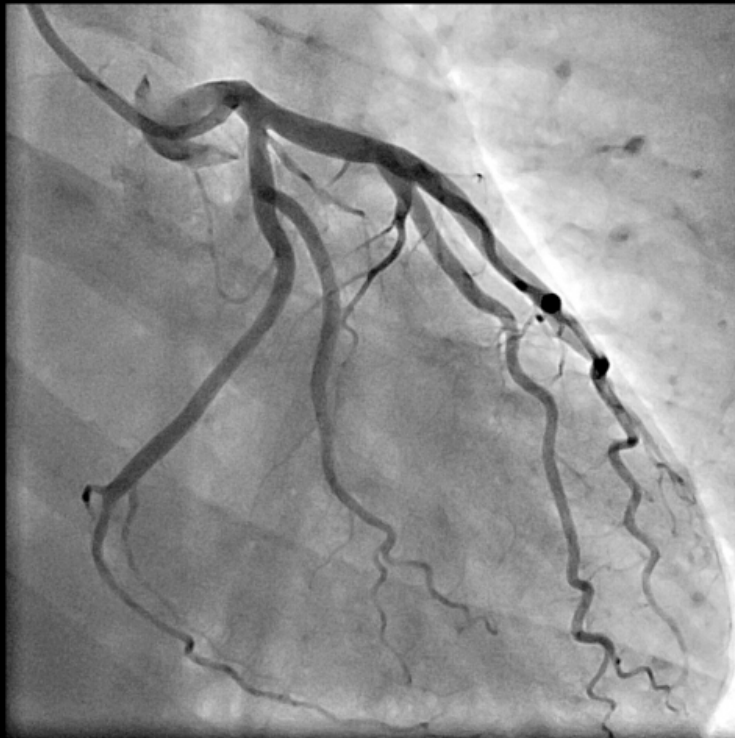



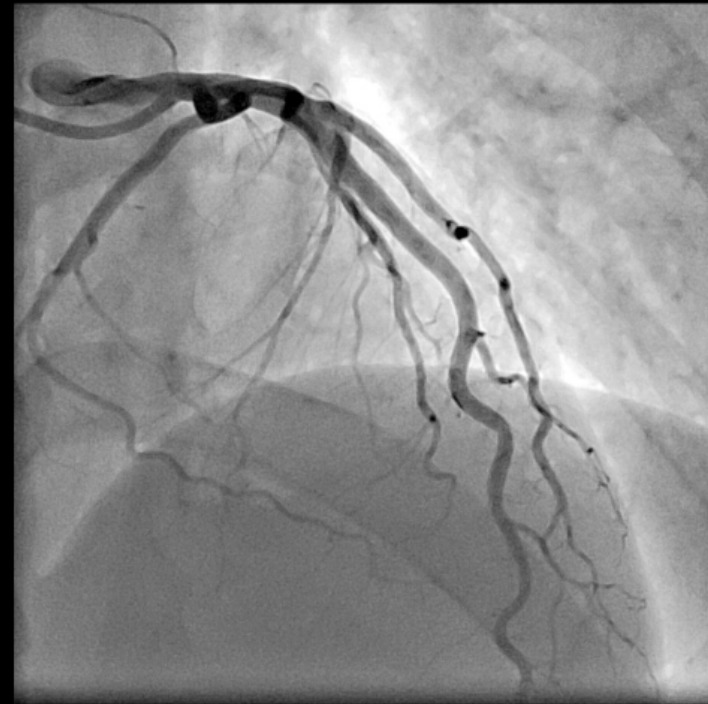
# Evaluation taille artère

## Intérêts

Contrôle coro à J3



Pic CPK 480 UI/L  
Bonne fonction VG



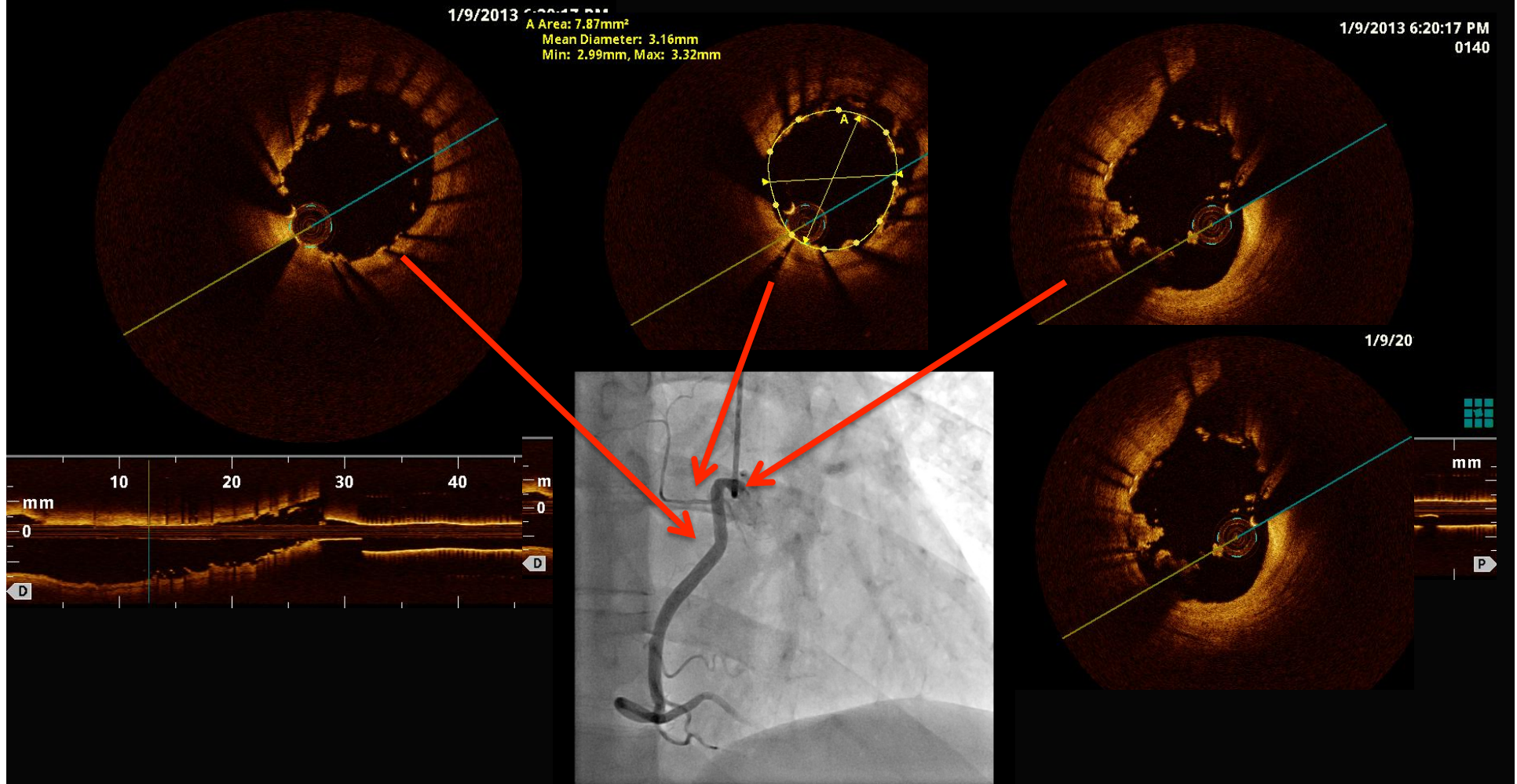


# Evaluation taille artère

Intérêts

Contrôle coro à J3

OCT Coronaire droite







# Evaluation taille artère

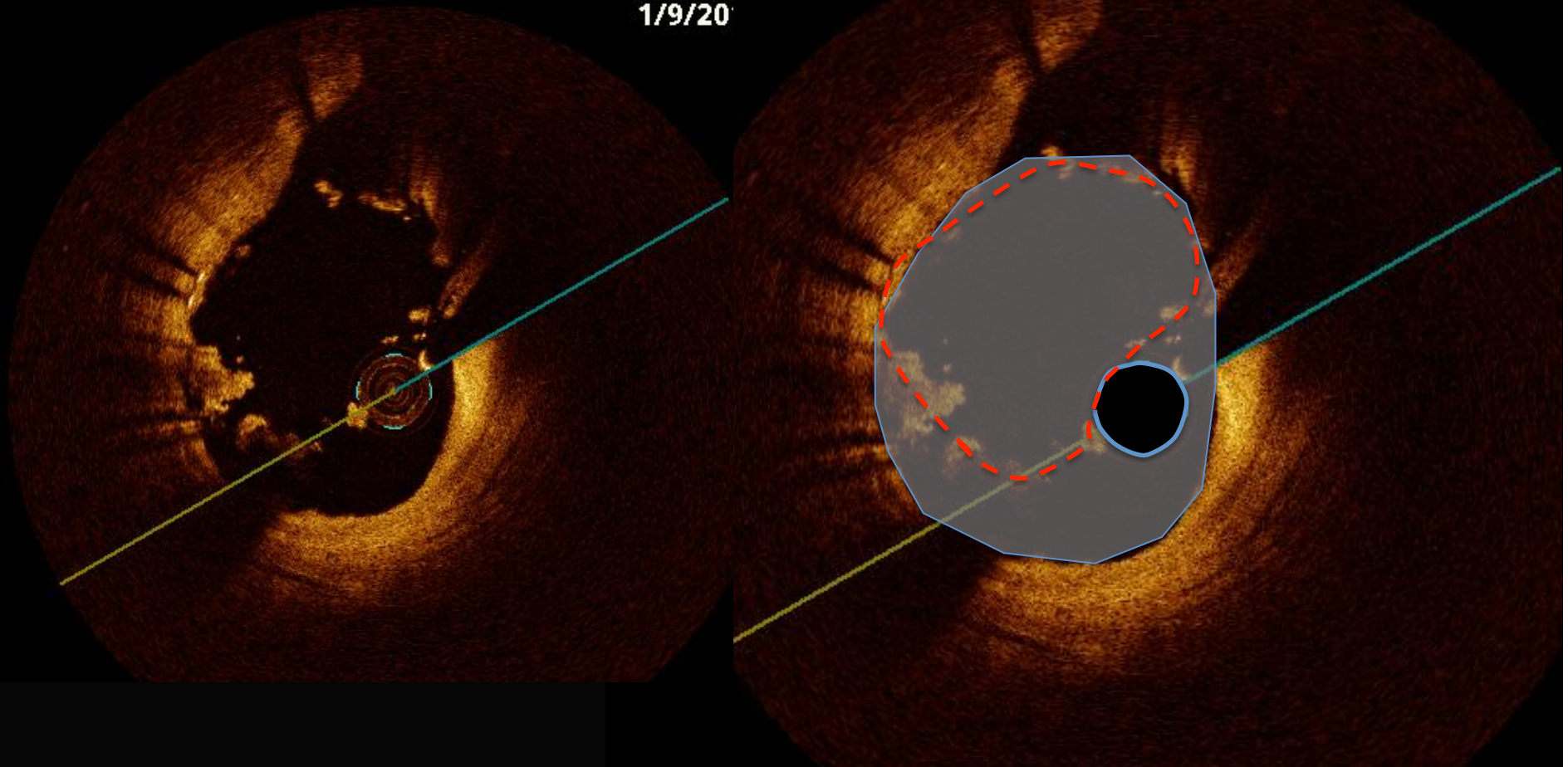
Intérêts

Contrôle coro à J3

OCT Coronaire droite

1/9/20

1/9/20



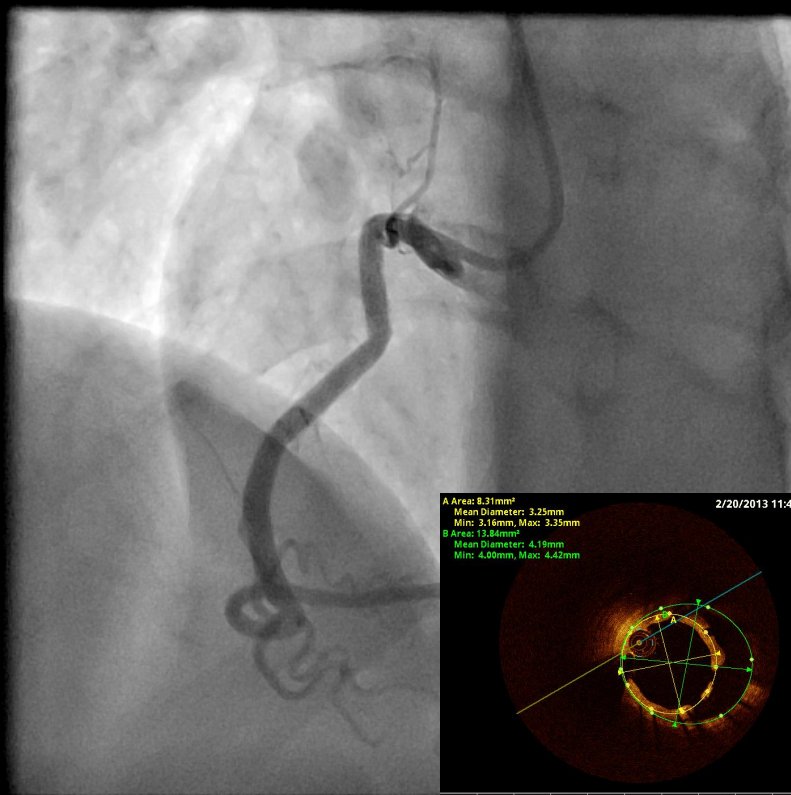


# Evaluation taille artère

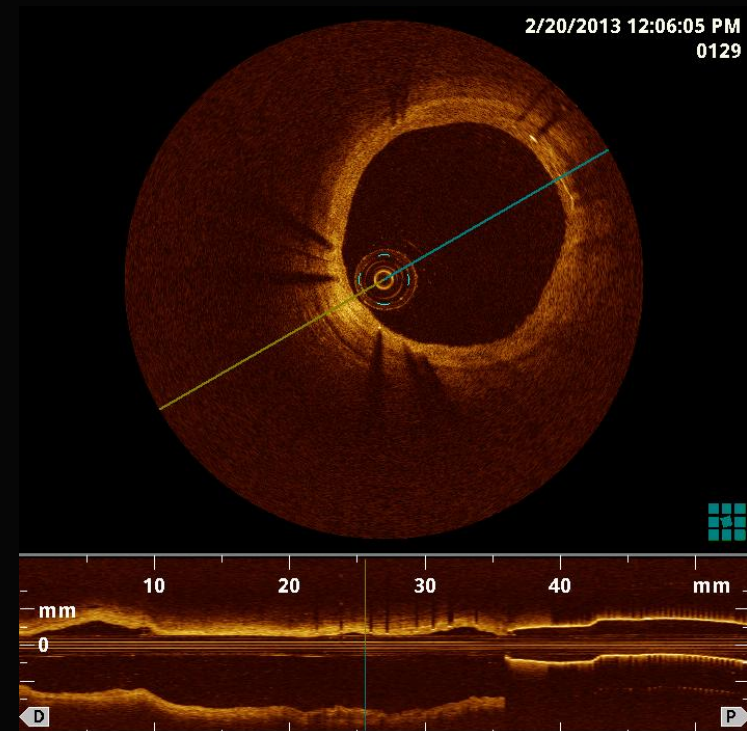
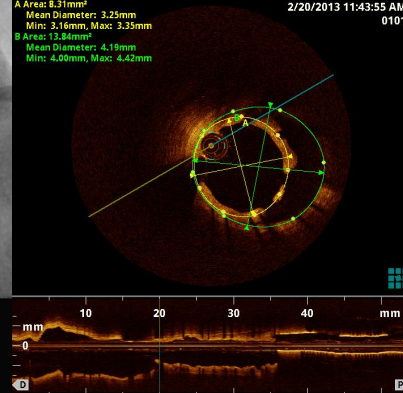
Intérêts

Contrôle coro à J30

Post-dilatation ballon  
Non-compliant 4.5mm



2/20/2013 11:43:55 AM  
0101  
A Area: 8.31mm<sup>2</sup>  
Mean Diameter: 3.25mm  
Min: 3.16mm, Max: 3.35mm  
B Area: 13.84mm<sup>2</sup>  
Mean Diameter: 4.19mm  
Min: 4.00mm, Max: 4.42mm



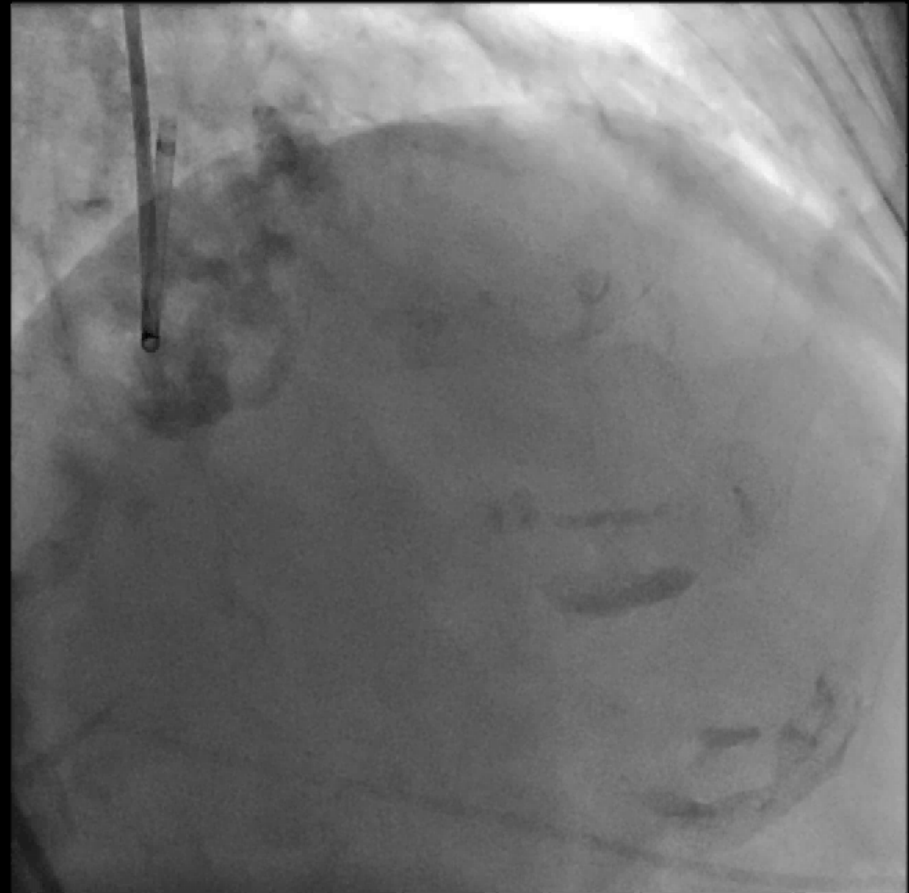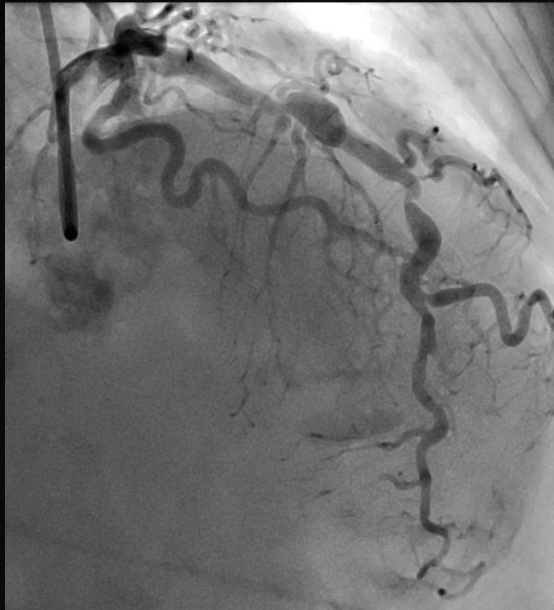




# Evaluation taille artère

## Intérêts

**Patiente 90 ans**  
**Bilan Rao**  
**Angor moindre effort**

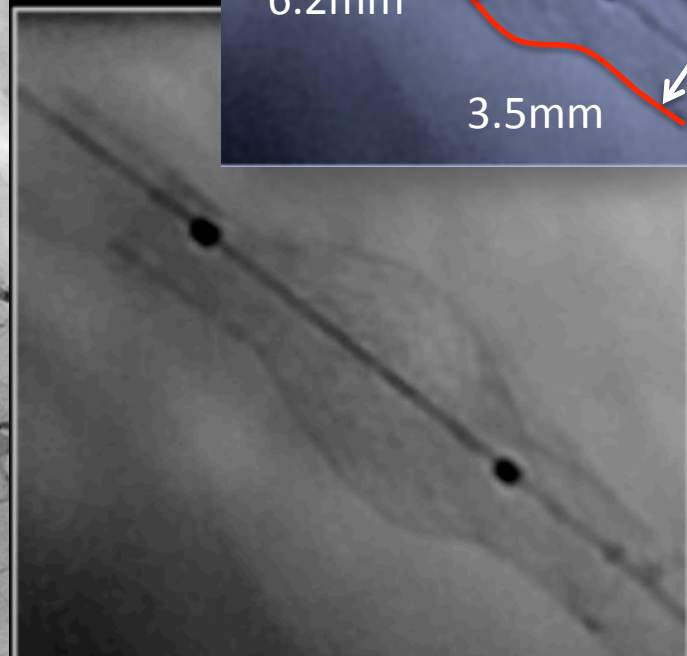
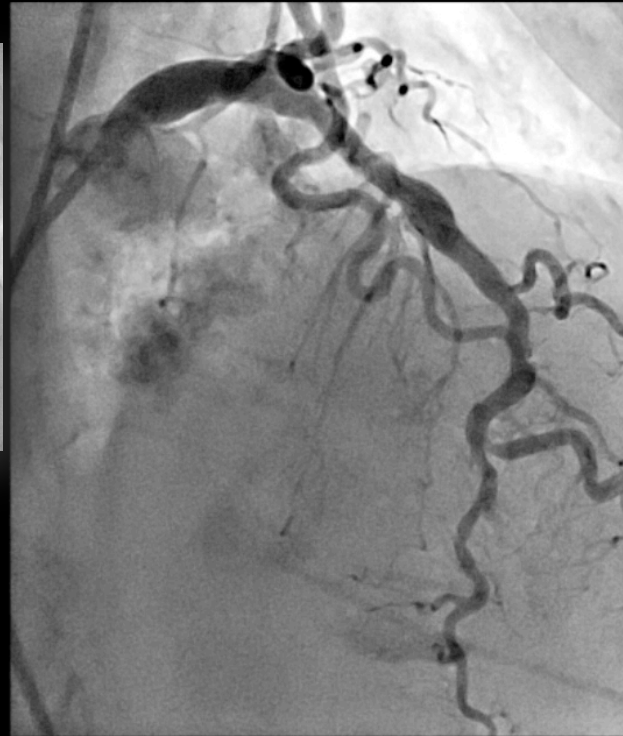
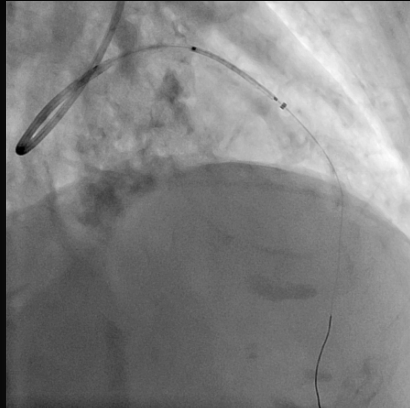




# Evaluation taille artère

## Intérêts

Angioplastie complexe  
Stenting IVA distale  
Stenting IVA 2 avec stentys 3;5-4.5 x22mm

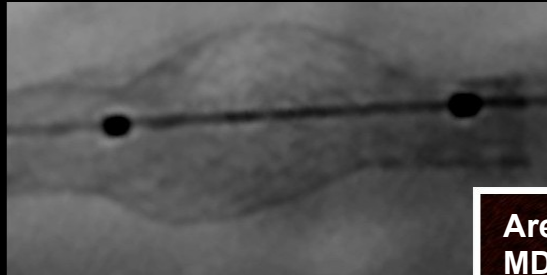

Post-dilatation ballon  
Non-compliant 4mm



# Evaluation taille artère

## Intérêts

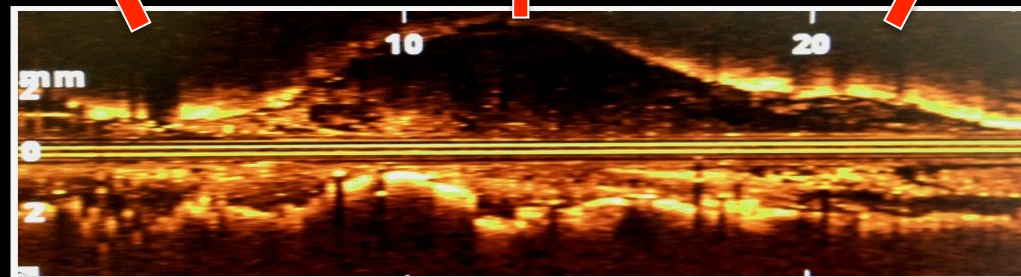


Area 12.47 mm<sup>2</sup>  
MD 3.98 mm

Area 30.2 mm<sup>2</sup>  
MD 6.2 mm

Axial view

Area 9.98 mm<sup>2</sup>  
MD 3.56 mm



Long view

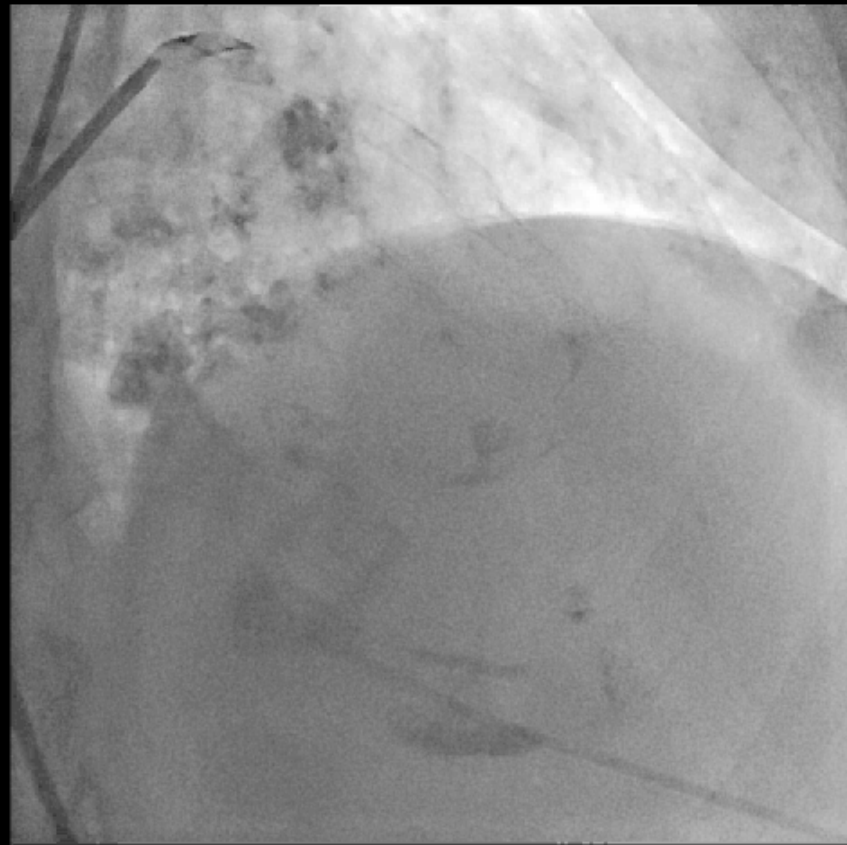



# Evaluation taille artère

## Intérêts

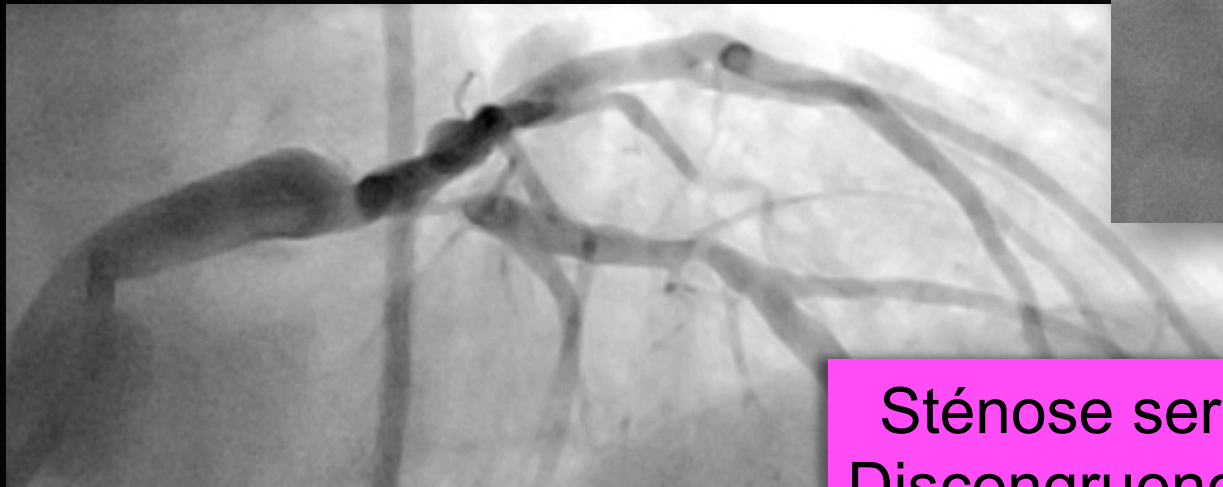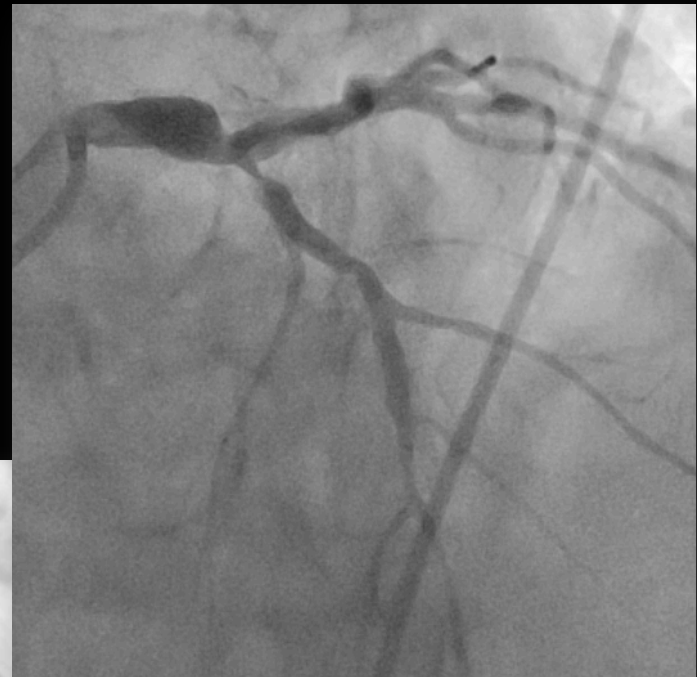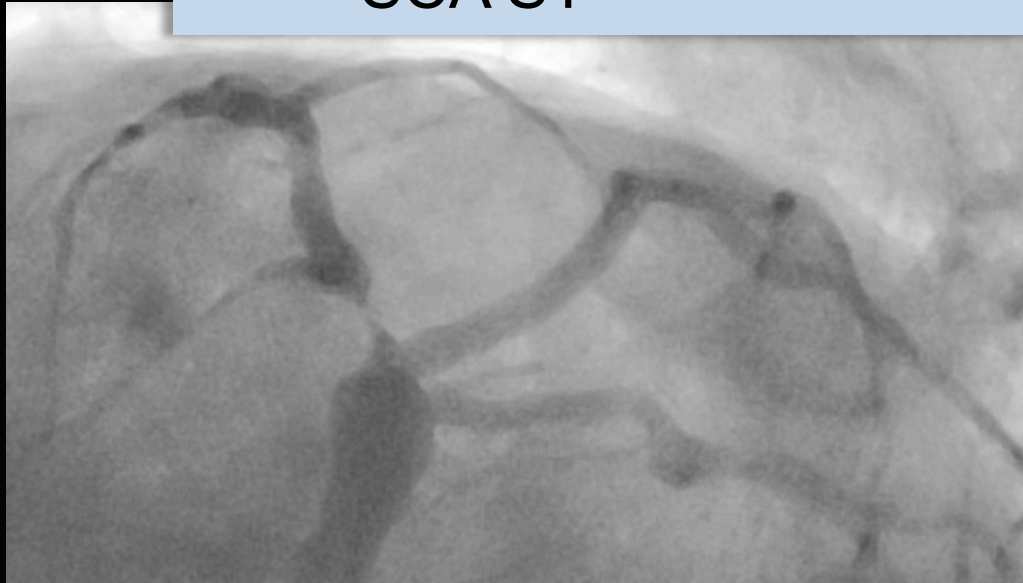
Evolution simple  
Pas evt à 6 mois



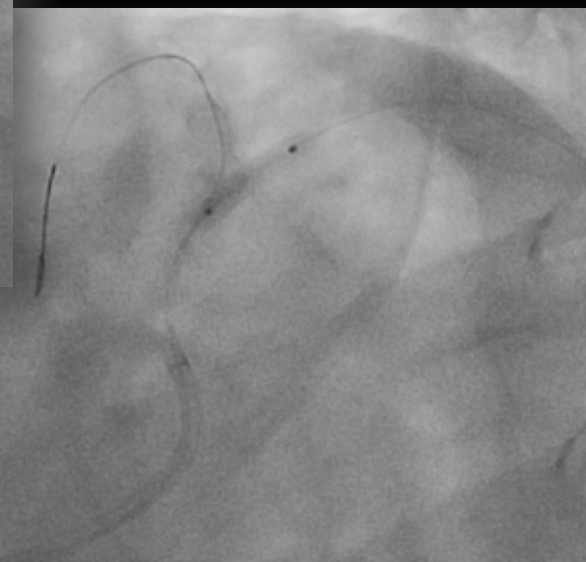
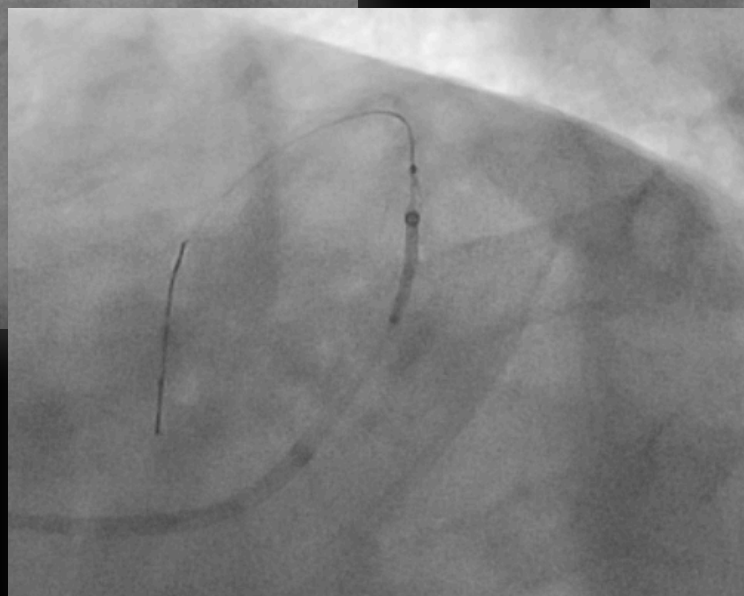
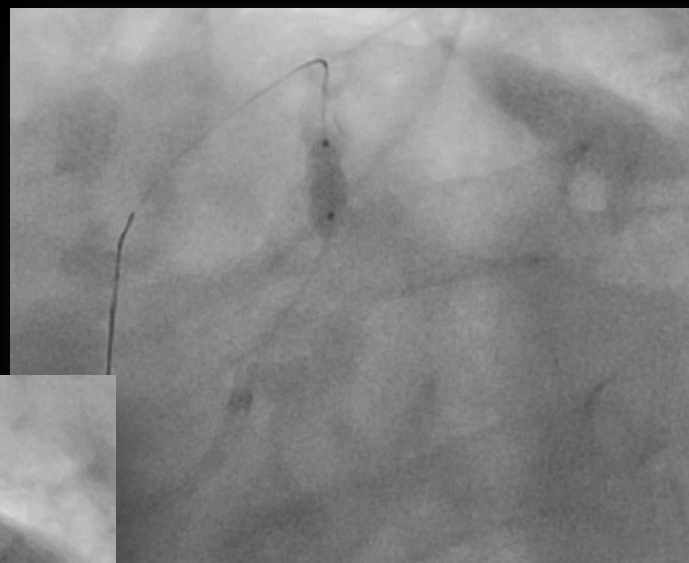
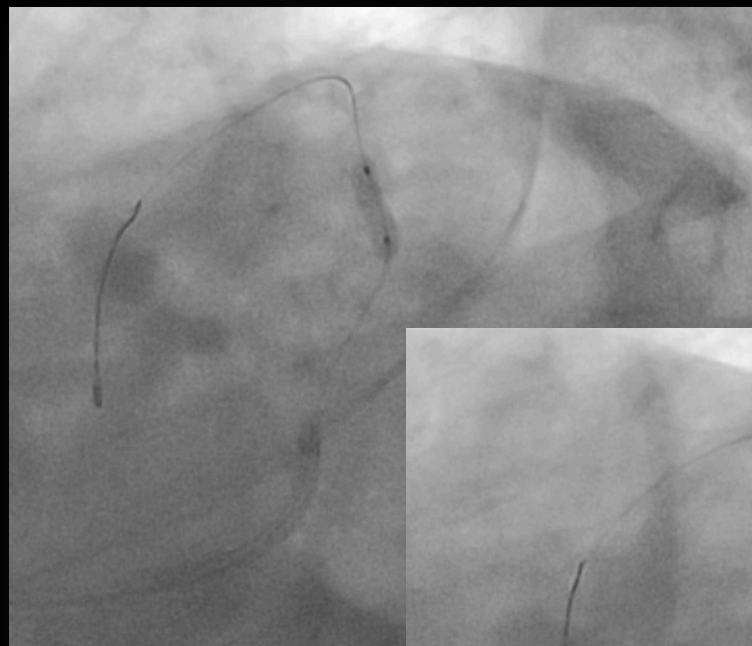


**Mr C. , 79 ans**

- Dyslipidémie, HTA, Obésité
- SCA ST-



Sténose serrée IVA proximale  
Discongruence calibre IVA/TC



Prédilatation


**Stentys® 3.5/4.5mm x 22mm**

Post-dilatation IVA

Post-dilatation 1<sup>ère</sup> diagonale

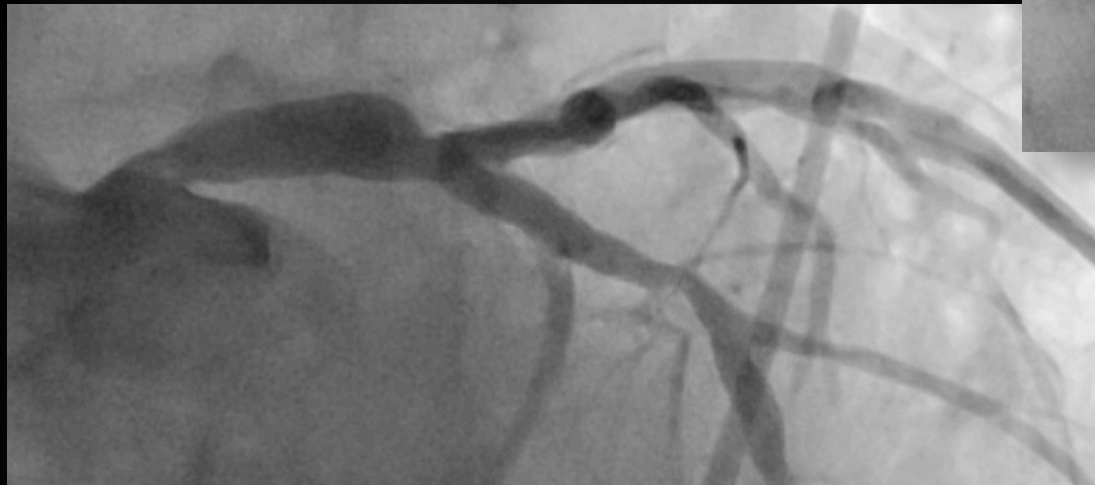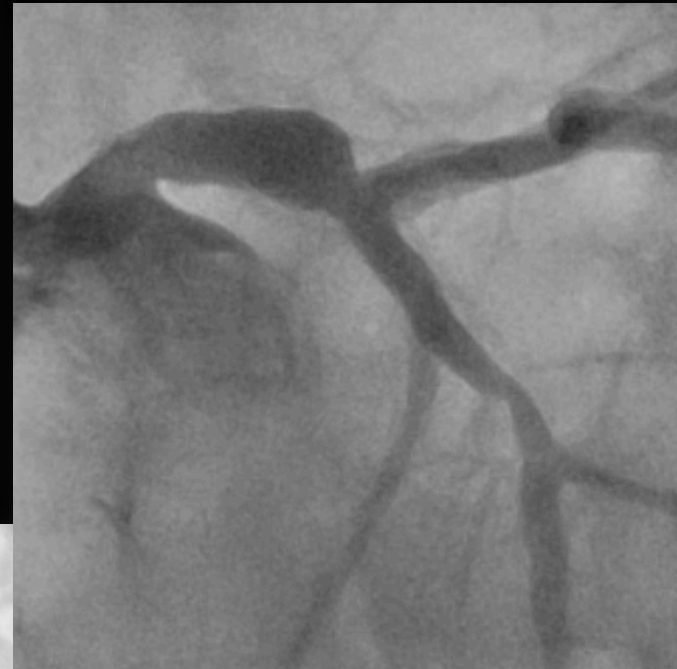
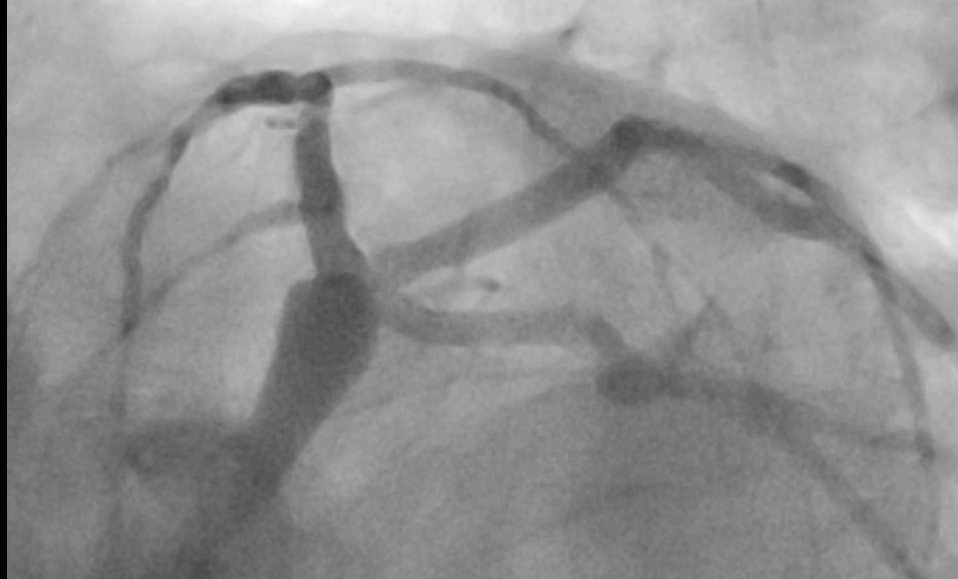


Grâce aux propriétés du Nitinol et connecteurs Kissing stent pas nécessaire



\* Except the first and last 2mm

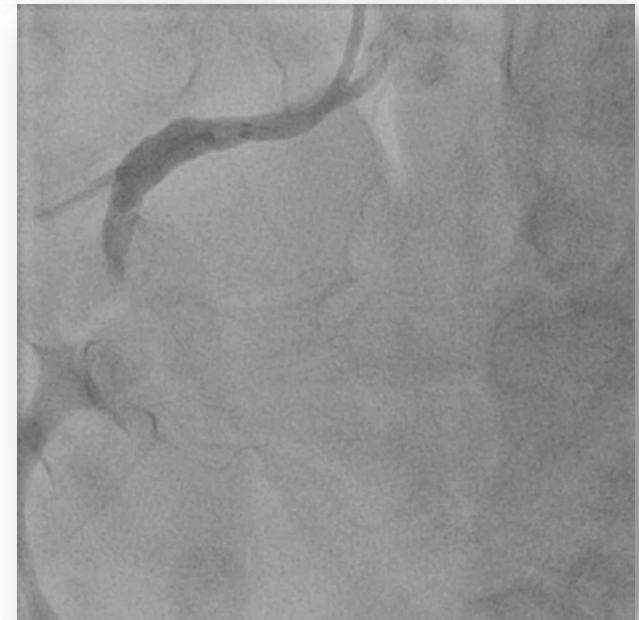
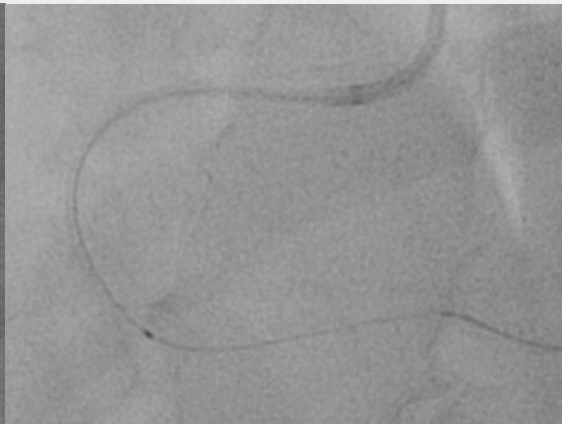
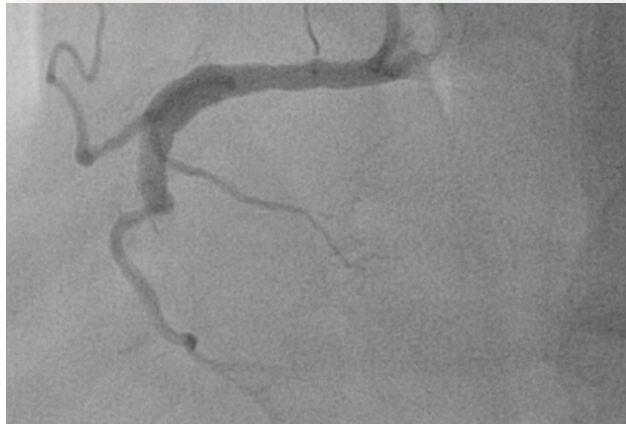# Résultat



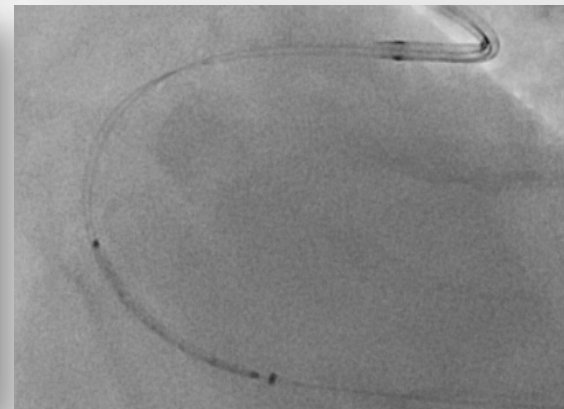
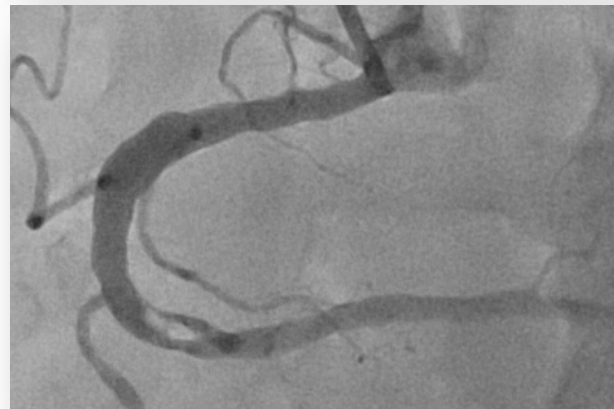
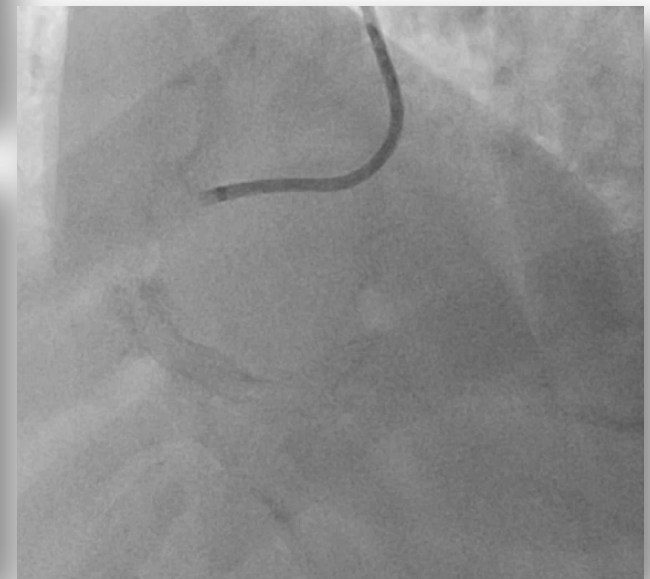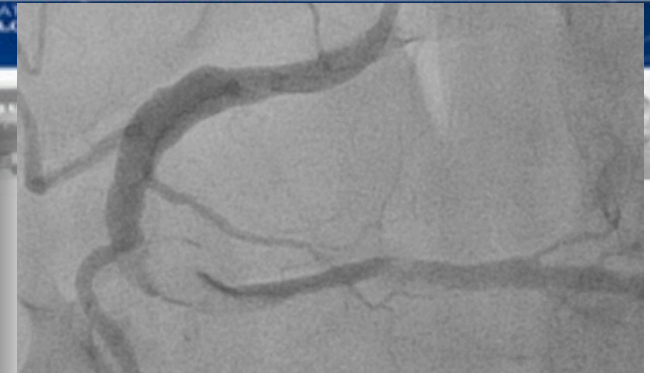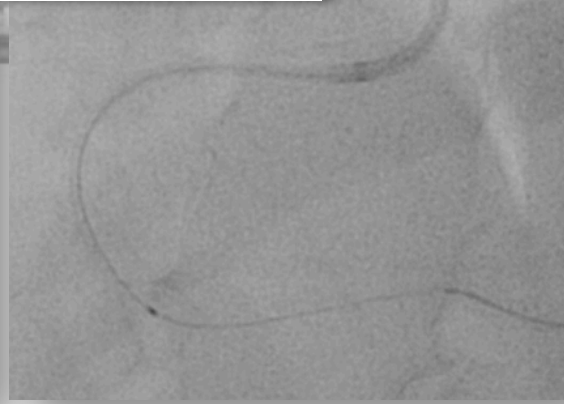
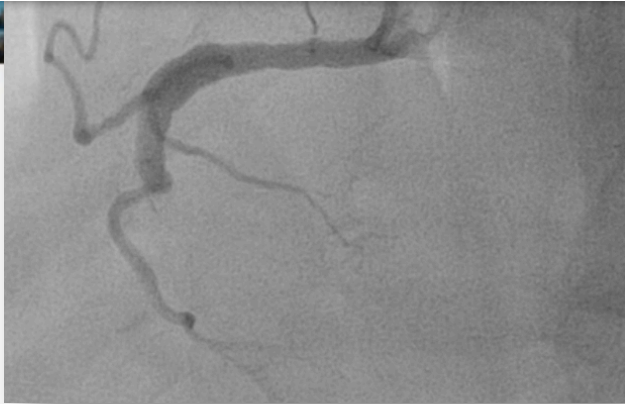




**Mr C., 69 ans, SCA ST+ inferieur**



**Mr C., 69 ans, SCA ST+ inferieur**

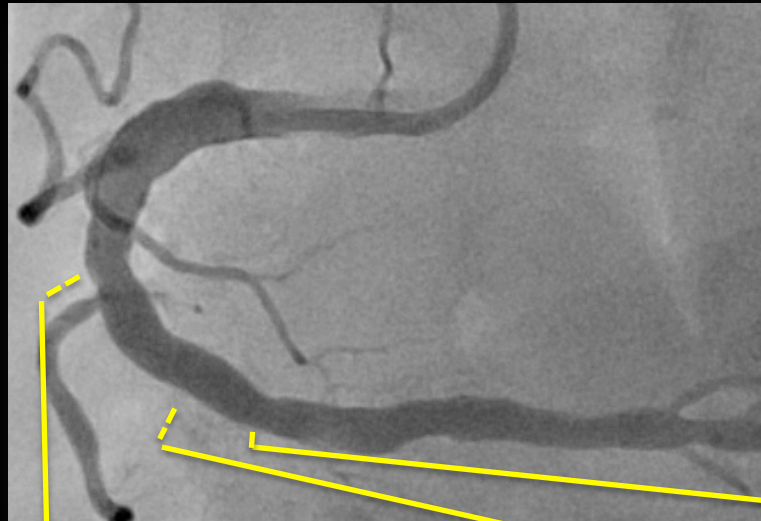


**Contrôle à J5**

**Stent auto-expandable**

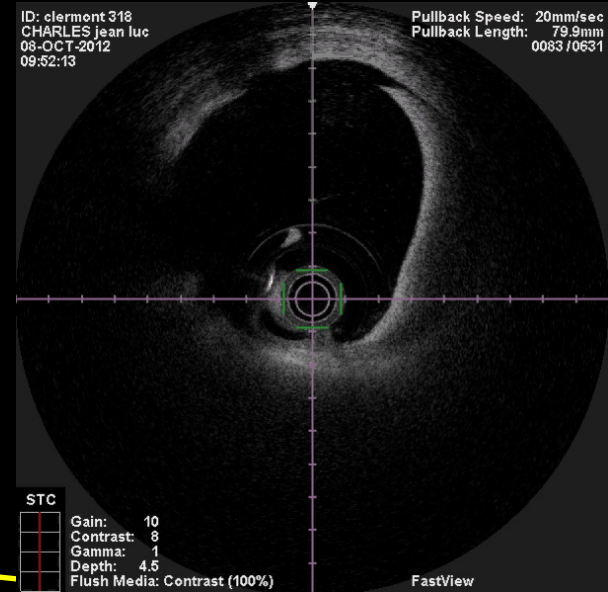


# Stent auto-expandable (OCT à 1 mois)



ID: clermont 318  
CHARLES jean luc  
08-OCT-2012  
09:52:13

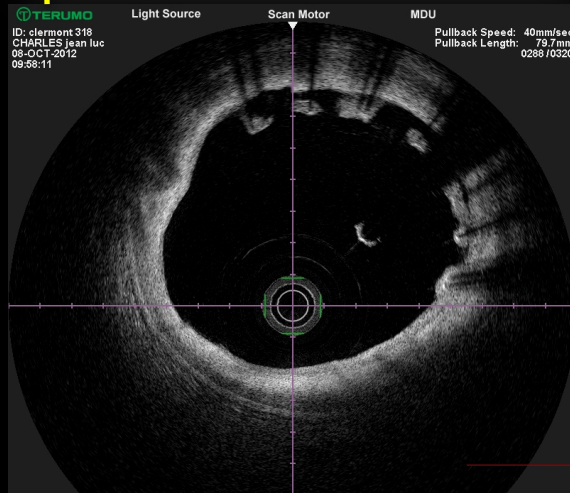
Pullback Speed: 20mm/sec  
Pullback Length: 79.9mm  
0083 / 0631



STC

Gain:	10
Contrast:	8
Gamma:	1
Depth:	4.5
Flush Media:	Contrast (100%)

FastView



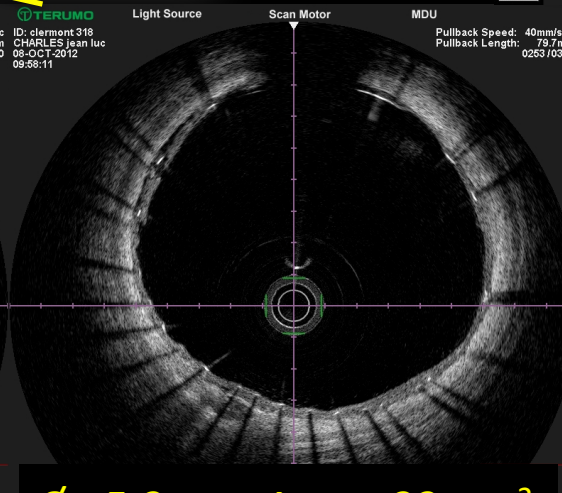
TERUMO  
ID: clermont 318  
CHARLES jean luc  
08-OCT-2012  
09:50:11

Light Source

Scan Motor

MDU

Pullback Speed: 40mm/sec  
Pullback Length: 79.7mm  
0288 / 0320



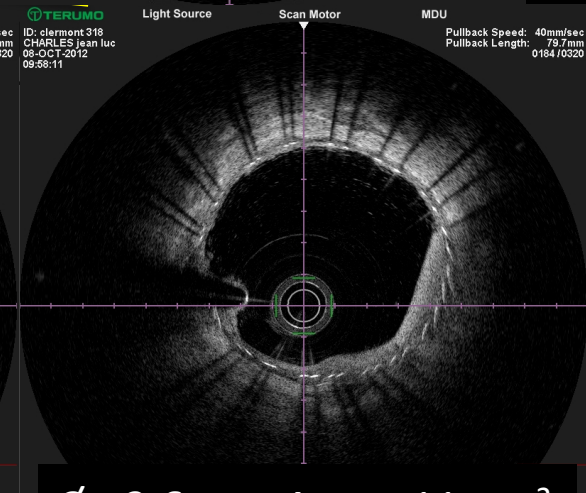
TERUMO  
ID: clermont 318  
CHARLES jean luc  
08-OCT-2012  
09:50:11

Light Source

Scan Motor

MDU

Pullback Speed: 40mm/sec  
Pullback Length: 79.7mm  
0263 / 0320



TERUMO  
ID: clermont 318  
CHARLES jean luc  
08-OCT-2012  
09:50:11

Light Source

Scan Motor

MDU

Pullback Speed: 40mm/sec  
Pullback Length: 79.7mm  
0184 / 0320

∅ = 5.2mm, Area = 23mm<sup>2</sup>

∅ = 3.6mm, Area = 11mm<sup>2</sup>

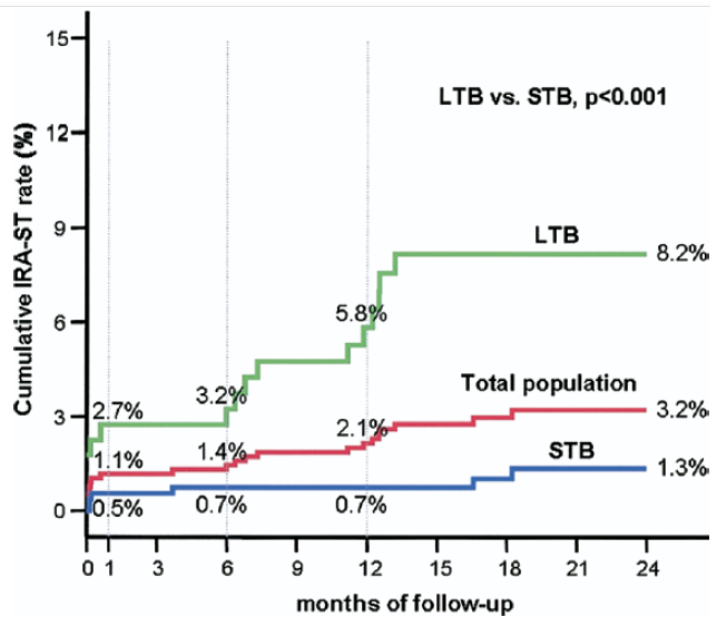


# Le stent auto-apposant STENTYS<sup>®</sup>

Intérêts

Résultats

## Thrombose tardive de DES en fonction du thrombus initial



Large thrombus burden  
(28% des SCA ST+)

risque x 6

Small thrombus burden





# Le stent auto-apposant STENTYS<sup>®</sup>

Intérêts

Résultats

**Late stent malapposition risk is higher after drug-eluting stent compared with bare-metal stent implantation and associates with late stent thrombosis**

Méta-analyse 2195 stents actifs, 2453 stents nus  
Contrôle IVUS entre 6 et 9 mois

**2.5 x plus de malappositions avec stents actifs**

Facteurs prédictifs : SCA, diabète

**Risque thrombose tardive x 6.5 quand malapposition tardive**



# Le stent auto-apposant STENTYS<sup>®</sup>

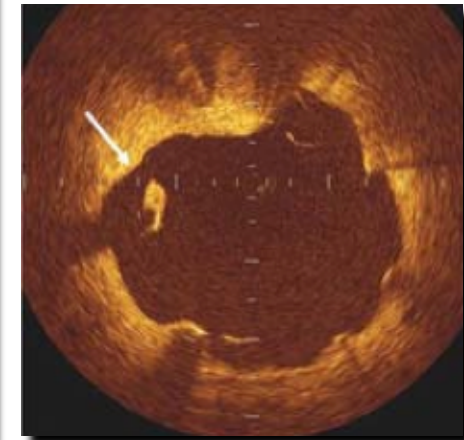
Intérêts

Résultats

## Relation Apposition – Thrombus en OCT

22 patients contrôlés à 10 mois post-implantation SES,  
analyse OCT par coupes :

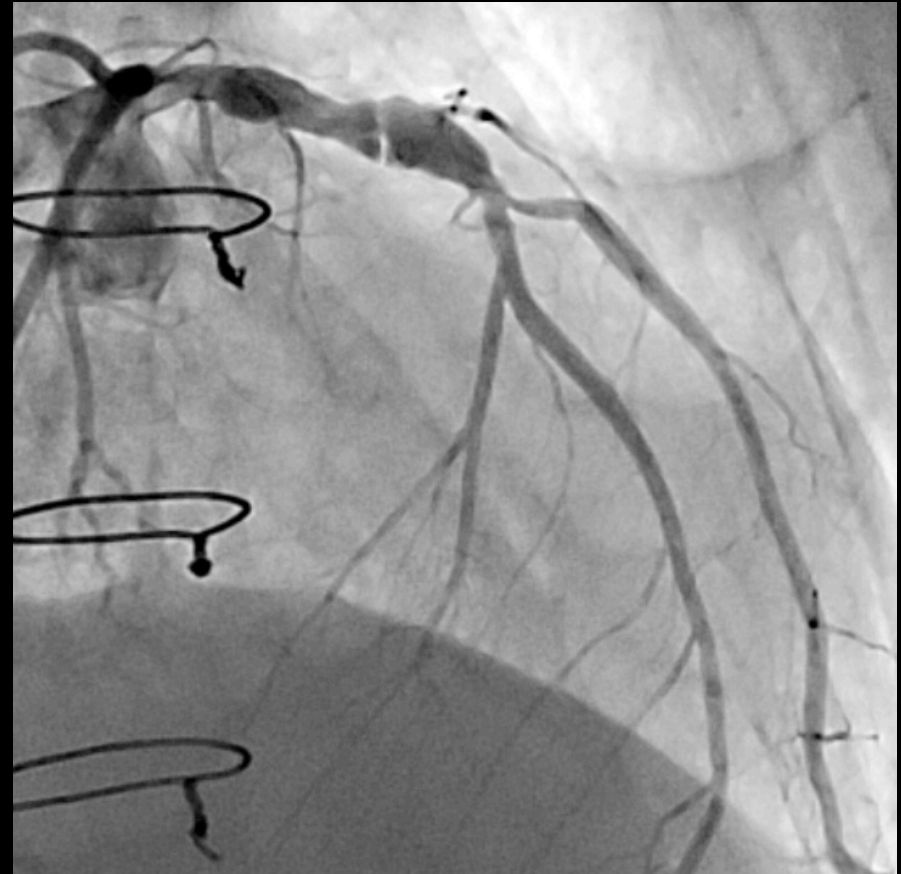	<b>Well apposed (n = 548)</b>	<b>ISA (n = 68)</b>	<b>P-value</b>
Number of detected struts	7.0 ± 0.8	7.1 ± 0.6	0.475
Presence and absence of thrombus			
Thrombus (n, %)	11 (2.0)	14 (20.6)	<0.001
No thrombus (n, %)	537 (98.0)	54 (79.4)	—
ISA dimensions			
ISA area (mm <sup>2</sup> )	0	0.12 ± 0.06	—



# Stent auto-expandable

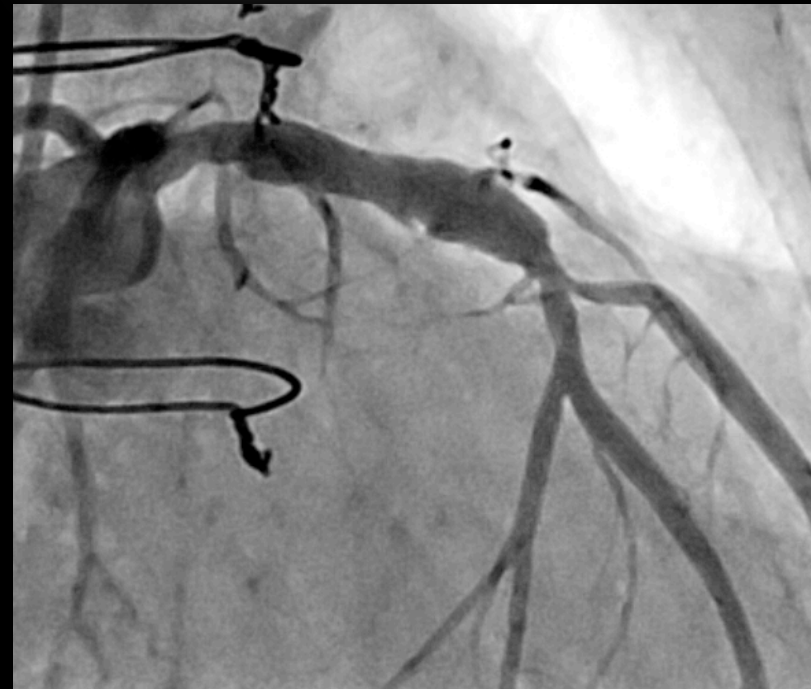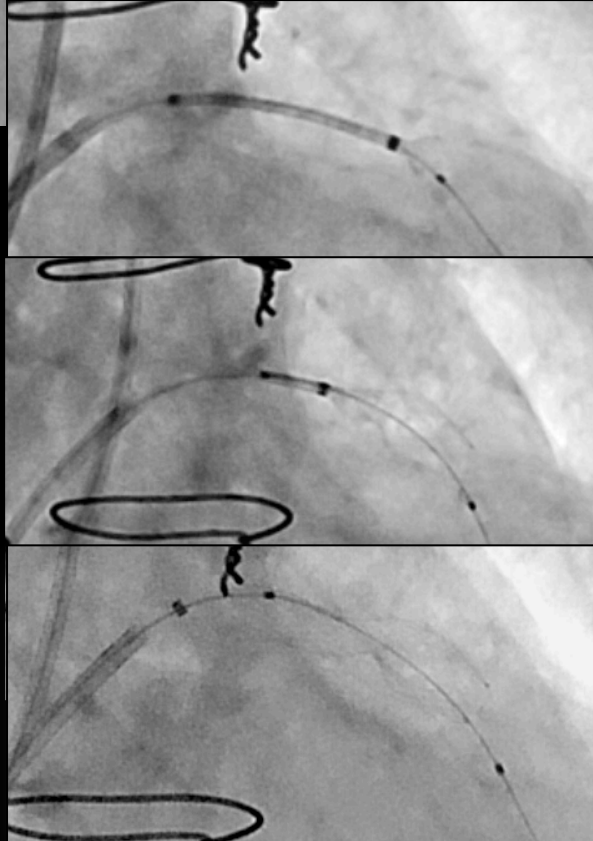
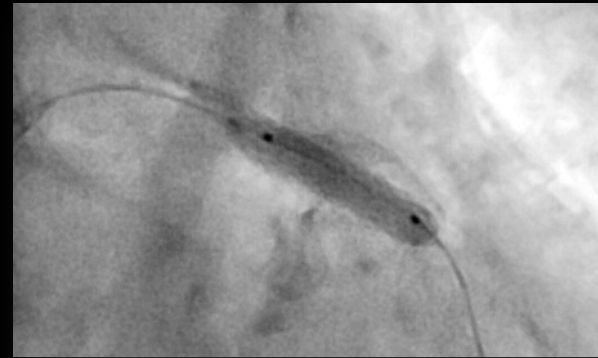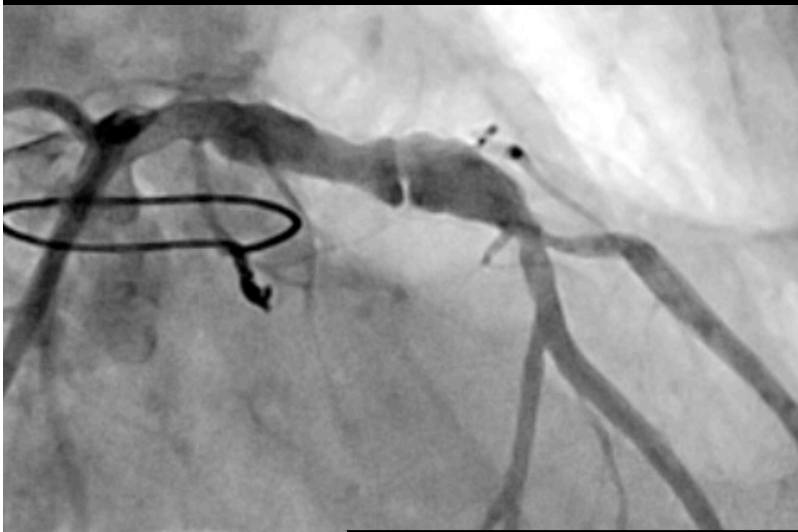
**Mr P. , 51 ans**

- , **Dyslipidémie**
- **Prothèse mitrale mécanique**
- **Angor moindre effort**

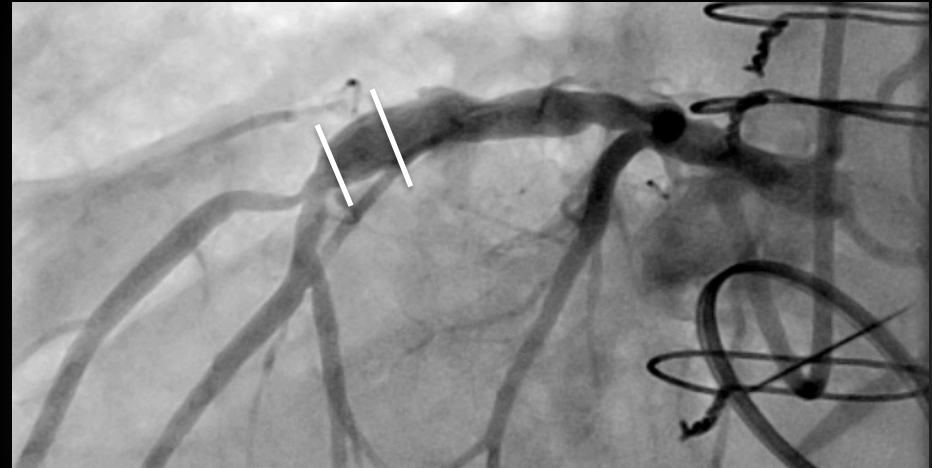




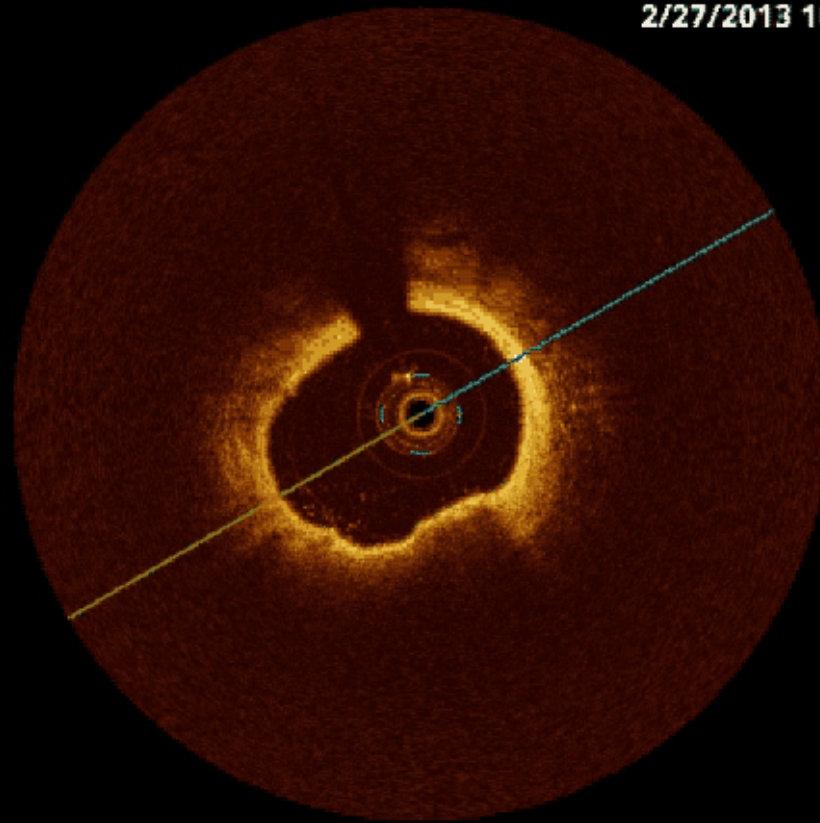
Self-expandable stent  
**Stentys® 3.5/4.5x22mm**  
Post-dilatation NBC 4.0mm



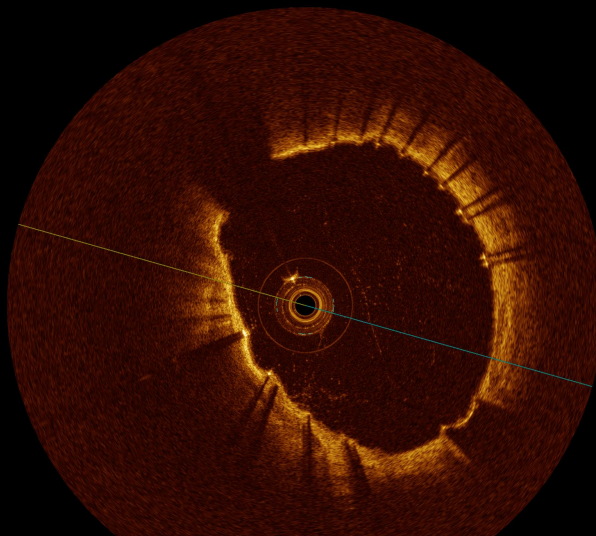
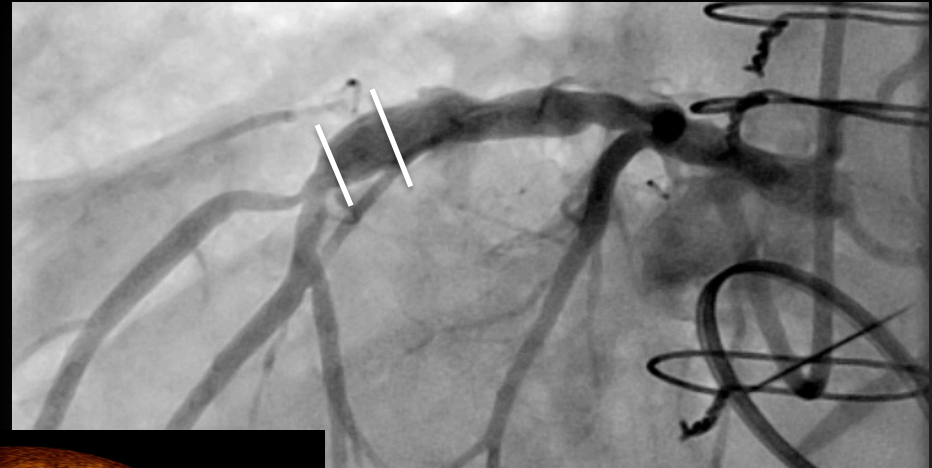
**OCT follow-up @ 4 months**  
*(Saint-Jude Medical)*



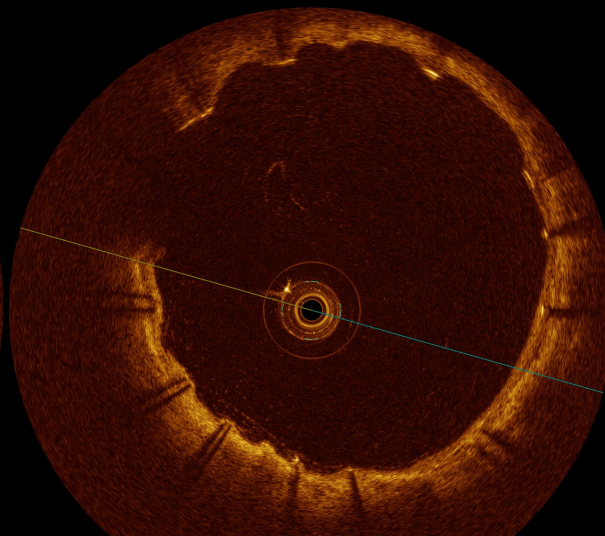
2/27/2013 10:29:01 AM  
0020



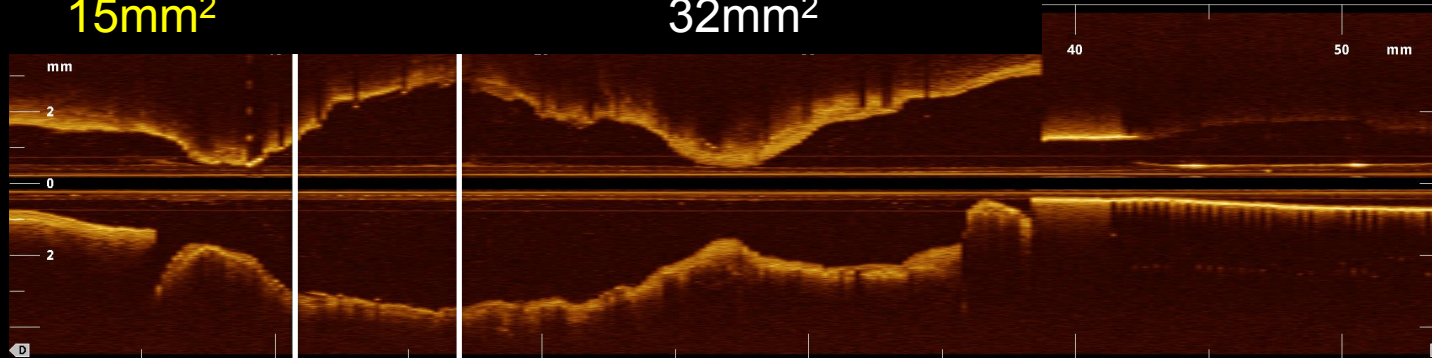
**OCT follow-up @ 4 months**  
*(Saint-Jude Medical)*



$\text{Ø} : 4.3\text{mm}$ , Surface=  
 $15\text{mm}^2$



$\text{Ø} : 6.4\text{mm}$ , Surface=  
 $32\text{mm}^2$





# Conclusions

**15<sup>e</sup> édition** www.appac.fr

BIARRITZ 5-6 ET 7 JUIN 2013

**APPAC**

ACTUALISATIONS ET PERSPECTIVES  
EN PATHOLOGIE CARDIOVASCULAIRE



**Intérêt stent auto-expandable :**

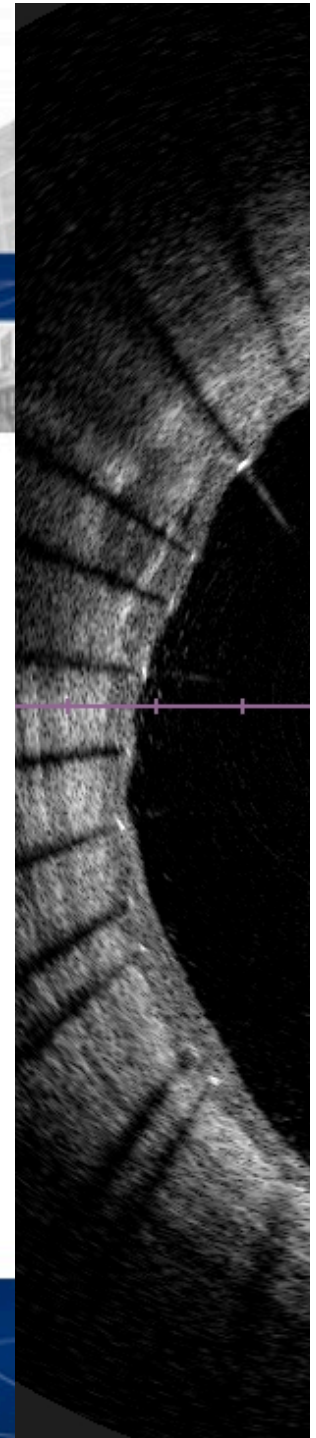
- diminuer malappositions
- adaptation diamètre artériel contexte SCA
- anévrismes

**Important de post-dilater**

## **Le Futur**

**Attente résultats apposition IV**

**Améliorer le profil ++**



15<sup>e</sup> édition [www.appac.fr](http://www.appac.fr)

BIARRITZ 5-6 ET 7 JUIN 2013

APPAC

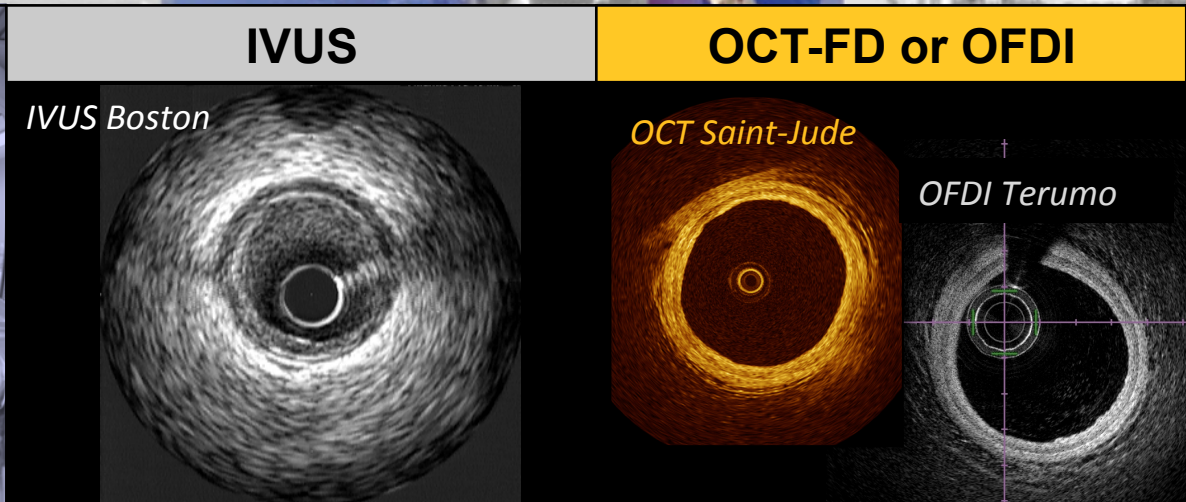
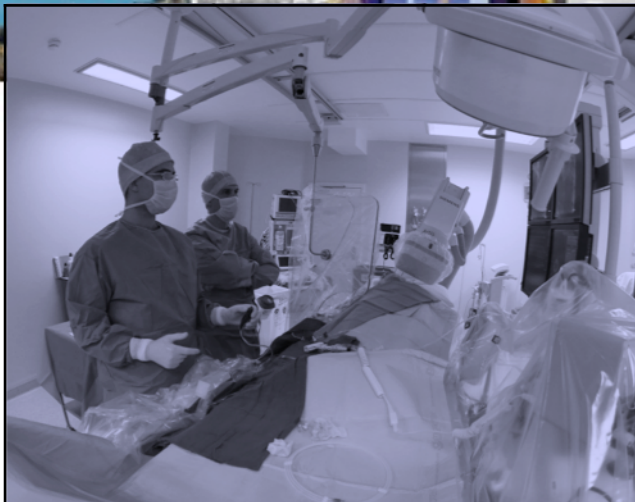ACTUALISATIONS ET PERSPECTIVES  
EN PATHOLOGIE CARDIOVASCULAIRE



[gsouteyrand@chu-clermontferrand.f](mailto:gsouteyrand@chu-clermontferrand.f)



# High resolution endocoronary imaging



	IVUS	OCT-FD or OFDI
Resolution	100-150 micrometers	<b>10-20 micrometers</b>
Size of imaging core	1.1 mm	0.9 mm
Frame Rate	30/s	100-150/s
Pullback Speed	1 mm/s	5-40 mm/s
Scan Area	10-15 mm	7 mm
Depth of penetration	4-8 mm	1-1.5mm
		Requires blood clearing